

Subcutaneous Emphysema as a Complication of Tonsillectomy: A Systematic Literature Review and Case Report

*Panagiotis Saravakos¹, Margaritis Taxeidis¹, Ioannis Kastanioudakis², Oliver Reichel¹

Abstract

Introduction:

Subcutaneous and mediastinal emphysema is a rare complication after tonsillectomy. This case presentation and literature review summarizes the existing literature on this unusual complication.

Materials and Methods:

This study presents a case of a 21-year-old man who developed a cervical subcutaneous emphysema 6 days after tonsillectomy, whereby conservative treatment produced spontaneous resolution. A proper analysis of this case also required undertaking a systematic search in MEDLINE/PubMed and SCOPUS electronic databases concerning this rare complication, without language restrictions.

Results:

Based on our criteria, we identified 41 reports including 43 individual cases, in which patients were mostly young and equally distributed between the genders (18 males and 23 females, two unknown). The treatment was mainly conservative and consisted of observation and/or antibiotic therapy.

Conclusion:

Subcutaneous or mediastinal emphysema is an uncommon complication after tonsillectomy. It is important that clinicians become aware of this rare complication, which requires a close monitoring of the patient.

Keywords:

Tonsillectomy, Mediastinal Emphysema, Subcutaneous Emphysema.

Received date: 4 Apr 2017

Accepted date: 6 Aug 2017

¹Department of Otorhinolaryngology, Head and Neck Surgery, Siloah St. Trudpert Hospital, Pforzheim, Germany.

²Department of Otorhinolaryngology Head and Neck Surgery, University Hospital of Ioannina, Ioannina, Greece.

*Corresponding Author

Department of Otorhinolaryngology, Head and Neck Surgery, Siloah St. Trudpert Hospital, Pforzheim, Germany
E-Mail: psaravakos@yahoo.com

Introduction

Tonsillectomy is one of the most common surgical procedures in otorhinolaryngology. Post-tonsillectomy, primary or secondary bleeding remains the most significant risk, but other common complications include damage to teeth, otalgia, odynophagia, throat infection, nausea, and vomiting (1,2). Less common immediate or intermediate complications following tonsillectomy or adenotonsillectomy include jugular vein thrombosis, Grisel syndrome (nasopharyngeal torticollis), mandible condyle fracture, infection, nasopharyngeal stenosis and velopharyngeal insufficiency (3,4). Moreover, another rare but potentially life-threatening complication following tonsillectomy is a cervicofacial subcutaneous emphysema (5-7).

In our case presentation, we attempted to summarize the incidence, clinical characteristics and proper therapeutic considerations of the post-tonsillectomy subcutaneous and/or mediastinal emphysema and to alert the medical community considering this rare complication. We also performed a systematic review of the literature aiming to collect case reports, summarize knowledge, and provide a basis for future studies.

Materials and Methods

Case presentation

A 21-year-old man suffering from recurrent chronic tonsillitis was admitted to our department for elective tonsillectomy. The medical, surgical and family history of the patient were unremarkable, and the preoperative physical examination revealed no abnormalities. Tonsillectomy was performed under general anesthesia with orotracheal intubation, using microscope-assisted extracapsular removal of the tonsils with the tonsil dissector. Hemostasis was achieved using cautery with bipolar forceps. The report described moderate tonsillar adhesions and no remarkable intraoperative bleeding.

On the third postoperative day, the patient complained of swelling in the left submandibular area. He denied symptoms of coughing or dyspnea. A physical examination revealed a painless left cervical swelling with crepitus extending from the left submandibular to the left supraclavicular region. There were no signs of local infection, and oral examination

revealed a normal wound healing process without any obvious mucosal tears at the tonsillar fossa. A computer tomography (CT) scan demonstrated a subcutaneous emphysema on both sides of the neck, not obstructing the airway (Fig.1).

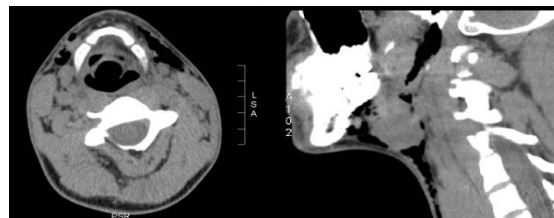


Fig 1: Computed tomography scan in the axial and sagittal planes showing air in the cervical subcutaneous tissues on both sides of the neck, especially on the left. There is also interruption of the air column in the left tonsillar lodge.

We administered broad-spectrum antibiotics with cephalosporin (cefuroxime) and metronidazole, as well as cough suppressants and laxatives. We instructed the patient to refrain from coughing and activities that would increase intrathoracic pressure (e.g. the Valsalva maneuver). The further course was uneventful, and the subcutaneous emphysema progressively resolved over the following days. The patient was discharged 10 days after surgery, whereby follow-up examinations revealed no further abnormal findings.

Literature review methods

We researched appropriate literature using a systematic computerized search in MEDLINE (via PubMed) and SCOPUS electronic databases. The keywords used included “tonsillectomy”, “adenotonsillectomy” and “emphysema” in various combinations, but with no language restrictions. We reviewed the references in each article and manually crosschecked them to ensure we included all applicable literature. Our study included all case reports containing original data relating to subcutaneous and/or mediastinal emphysema after performing tonsillectomy or combined adenotonsillectomy. However, we excluded pneumoperitoneum cases without mediastinal or cervical emphysema, and excluded subcutaneous emphysema cases after dental procedures. Descriptive statistical analysis was performed to describe and summarize data. A t-test for independent samples was performed to analyze differences between the two gender groups

(mean values and standard deviation, SD). A P-value<0.05 was considered statistically significant. All statistical procedures were conducted using IBM SPSS Version 20.0.

Results

As depicted in the flow chart (Fig.2), we found 66 records in the medical literature, eliminating 13 after evaluating the title and the abstract as insufficient to meet the inclusion criteria. We also excluded nine other records as they did not provide sufficient information concerning patient characteristics and therapeutic modality. Ultimately, we maintained the remaining 41 records (43 individual cases) for this study, as chronologically presented in Tables 1 and 2 (5, 6, 8-44). The first report was published in 1923, and we analyzed all subsequent reports. Patient ages ranged widely from 2 to 55 years (with a mean of 24.5, median 22, standard deviation 15.9) and included 18 males and 23 females (2 missing data) (Fig. 3).

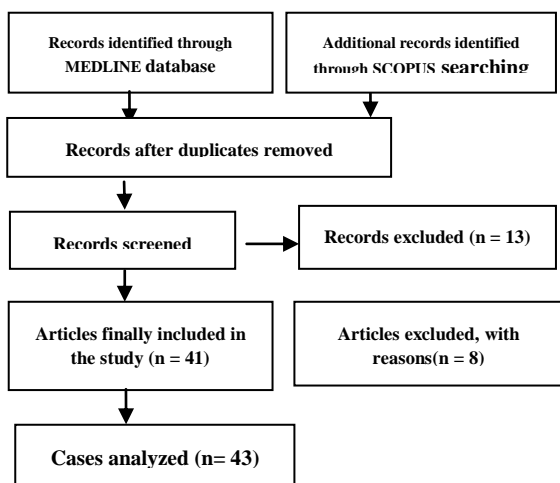


Fig 2: Flow chart presenting the design of the systematic review.

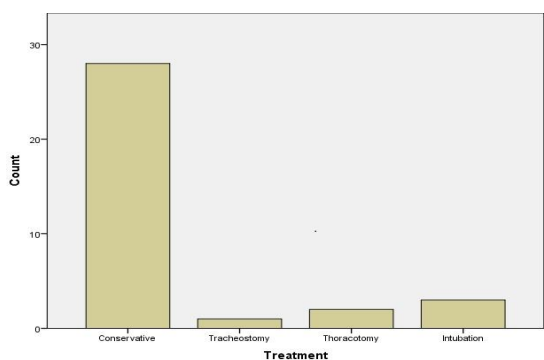


Fig 3: Box plot showing the median and range of the age concerning the occurrence of the subcutaneous emphysema. A statistical analysis showed no

significant difference for age of occurrence between the genders, with a p-value of 0.525.

The treatment was either conservative including observation and/or antibiotic therapy or interventional/surgical with re-intubation, tracheostomy or thoracotomy. More specifically, two cases required a thoracotomy, three cases required a re-intubation, and in one case a temporary tracheostomy was needed (Fig.4). Concerning the time of the onset of emphysema, in the majority of cases (75%) this occurred on the day of surgery, while only 5% of cases developed emphysema after the third postoperative day (Fig.5).

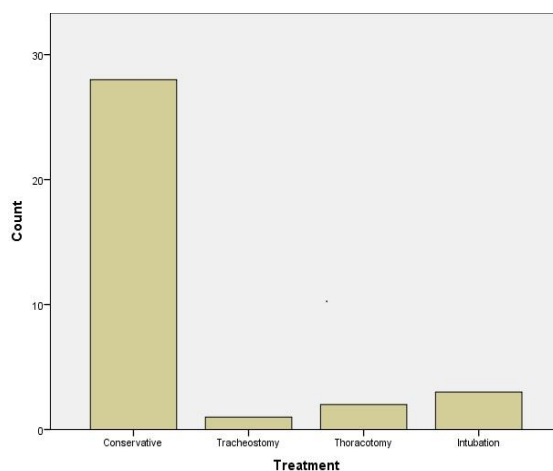


Fig 4: Histogram presenting the different methods of treatment of the subcutaneous emphysema. The treatment was either conservative, including observation and/or antibiotic therapy or interventional/surgical with re-intubation, tracheostomy or thoracotomy. Two patients required a thoracotomy, three patients a re-intubation and one patient required a temporary tracheostomy.

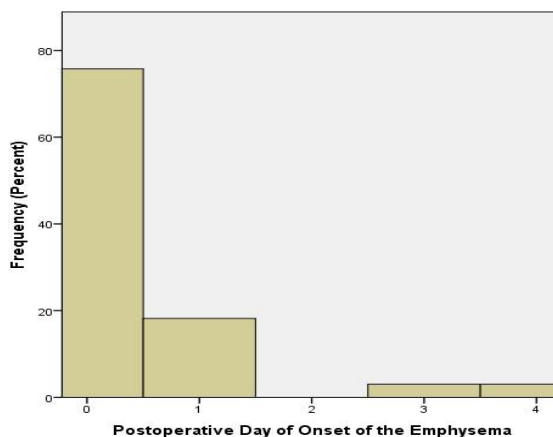


Fig5: Time of occurrence of subcutaneous emphysema after tonsillectomy. In the majority of cases, the complication occurred on the operation day or on the first postoperative day.

Table 1: Reported cases of subcutaneous or mediastinal emphysema as a complication of tonsillectomy (years 2000–2015)

Patient #	Year of publication	Author	Patient age	Gender	Time of onset	Treatment
1	2015	Tran et al. (40)	30	f	4 days	Antibiotics
2	2014	Bizaki et al. (12)	29	f	14 hours	Antibiotics
3	2014	Yelnoorkar et al. (43)	18	m	36 hours	Antibiotics
4	2014	Al Jabr et al. (8)	43	m	4 days	Antibiotics
5	2013	Sachdeva (35)	54	m	1 hour	Antibiotics
6	2013	Koukoutsis et al. (45)	21	f	First postoperative hours	Antibiotics
7	2012	Randrup et al.	?	f	?	?
8	2011	Al Omari et al. (9)	?	f	?	?
9	2011	Wahid et al. (41)	?	?	?	?
10	2011	Durchholz et al. (14)	?	?	?	?
11	2010	Kim et al. (18)	36	f	First day	Antibiotics
12	2009	Al-Layla et al. (10)	20	f	Immediately	Antibiotics
13	2009	Hung et al. (6)	37	m	Immediately	Intubation, antibiotic, parenteral nutrition
14	2009	Piotrowsi et al. (29)	6	m	?	Intubation, thoracotomy, antibiotics
15	2009	Melgaard (46)	45	f	?	?
16	2007	Siedek et al. (37)	20	f	Immediately	Antibiotics
17	2006	Villagra Siles et al. (47)	49	f	First day	Antibiotics
18	2005	Patel et al. (28)	31	m	6 hours	Antibiotics
19	2005	Lima et al. (20)	25	m	4 hours	Antibiotics
20	2005	Gillot et al. (5)	52	f	2 hours	Intubation, antibiotics
21	2005	Gillot et al. (5)	43	f	2 days	Cervical surgical drainage (abscess), intubation, antibiotics
22	2005	Shine et al. (36)	7	f	20 minutes	Antibiotics
23	2004	Stewart et al. (38)	31	f	Immediately	Tracheostomy, antibiotics
24	2004	Watanabe et al. (42)	24	m	First day	Antibiotics
25	2003	Nishino et al. (27)	55	f	8 hours	Antibiotics
26	2003	Fechner et al. (15)	21	f	Intraoperatively	Antibiotics
27	2003	Marioni et al. (23)	34	f	5 hours	Antibiotics
28	2001	Miman et al. (26)	11	m	Immediately	Antibiotics
29	2000	Tanaka et al. (48)	18	m	3 hours	Conservative

?=information not available; m=male; f=female Entries not included in the descriptive statistics due to missing data are represented in italics

Table 2: Reported cases of subcutaneous or mediastinal emphysema as a complication of tonsillectomy (years 1924–1999)

Patient #	Year of publication	Author	Patient age	Gender	Time of onset	Treatment
1	1998	Ruiz Gómez et al. (34)	43	m	?	?
2	1997	Hampton et al. (17)	?	?	?	?
3	1997	Hampton et al. (17)	?	?	?	?
4	1997	Lopez Gonzalez et al. (21)	Child	?	?	?
5	1997	Braverman et al. (13)	22	f	2 hours	Conservative
6	1990	Rous et al. (33)	8	?	?	?
7	1986	Giussan et al. (16)	?	?	?	?
8	1978	Luk'ianenko et al. (22)	?	?	?	?
9	1973	Prupas et al. (31)	22	m	14 hours	Observation
10	1962	Pratt et al. (30)	9	f	?	Thoracotomy
11	1960	Zivkovic et al. (44)	?	?	?	?
12	1958	Andersen et al. (11)	8	f	1 day	Conservative
13	1957	McGreevy et al. (24)	?	?	?	?
14	1955	Ferguson et al. (49)	4	f	3 hours	Thoracotomy, blood transfusion
15	1954	Knutson et al. (50)	6	m		Antibiotics
16	1953	Kazantseva et al. (51)	?	?	?	?
17	1953	Silverman et al. (52)	8	m	10 hours	Antibiotics
18	1952	Tezel et al. (53)	?	?	?	?
19	1936	Baker et al. (54)	27	f	1 day	Observation
20	1930	von Hofe (55)	2	m	Immediately	Conservative
21	1930	von Hofe (55)	4	f	Immediately	Conservative
22	1930	von Hofe (55)	2,5	m	Immediately	Conservative
23	1923	Stein (56)	7	m	Immediately	?
24	1924	Rosenbaum (57)	35	f	Immediately (10 minutes)	Conservative

?=information not available; m=male; f=female Entries not included in the descriptive statistics due to missing data are represented in italics

Discussion

Subcutaneous emphysema is a rare complication following procedures in the oropharyngeal or tracheobronchial area. The exact pathogenic mechanism remains unclear, but there are two main theories.

First, an important potential cause is the anesthetic procedure itself. More specifically, emphysema may result from a tear in the tracheobronchial mucosa or laryngeal trauma occurring during passage of the endotracheal tube, through overinflation of the cuff of the endotracheal tube, by excessively high alveolar pressure, or because of a malfunction of the ventilator during intubation. Congenital dehiscence in the mucosa, such as bullae, clefts or laryngoceles may also predispose to development of postoperative surgical emphysema (6, 58-60). Iatrogenic tracheal injury due to orotracheal intubation is a rare entity, with an incidence of approximately 0.005% when a single-lumen tube is used (61). In cases of airway lesions, the air enters the mediastinum and, from there, the subcutaneous tissues of the neck. However, many cases, including the present case report, describe an isolated subcutaneous emphysema without mediastinal involvement, which cannot be easily explained by the above-mentioned mechanism. Furthermore, one case was reported after performing tonsillectomy under local anesthesia, supporting the pathogenic theory of penetration of the tonsillar bed during tonsillar removal or during injection of local anesthetic (33). In our case, there was no difficulty in the tracheal intubation.

The second pathogenic mechanism involves a mucosal and muscular tear of the pharynx and air entry in the parapharyngeal space. This mechanism involves the structures intervening between the tonsillar fossa and the parapharyngeal space as well as the mediastinum. The tonsillar capsule is a portion of the pharyngobasilar fascia covering the deep aspect of the tonsil and extending into it to form septa that carry the nerves and blood vessels. Loose connective tissue attaches the tonsillar capsule, covering the pharyngeal muscles, which allows easy removal by dissection of the capsule from the muscle superficial to the pharyngobasilar fascia in the peritonsillar space. However, in the case of recurrent tonsillitis, adhesions to the underlying muscle make the

extracapsular dissection difficult. This fascia covers the superior constrictor muscle. Deeper lies the buccopharyngeal fascia, a part of the visceral division of the middle layer of the deep cervical fascia. The buccopharyngeal fascia separates the pharyngeal muscular wall from spaces that laterally surround it, covering the constrictor muscles and the buccinator muscle (62) (Fig.6). A rough preparation of the tonsillar capsule can damage the buccopharyngeal fascia, allowing air to enter into the parapharyngeal space. Furthermore, the visceral layer extends into the thorax around the trachea and esophagus. Consequently, the emphysema can extend into the superior mediastinum, causing a pneumomediastinum with symptoms of respiratory deficiency.

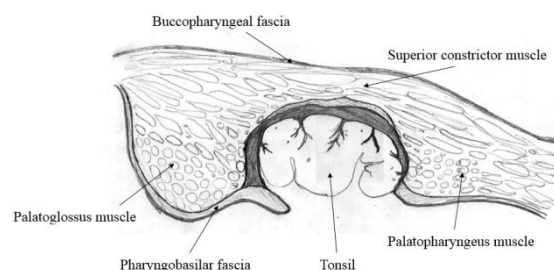


Fig 6: Palatine tonsil and its surrounding fasciae.

After taking into consideration the underlying pathophysiological mechanisms, the question remains as to what measures the surgeon should employ to reduce the possibility of a subcutaneous emphysema after a tonsillectomy. Preventive measures include careful surgical dissection of the tonsils to prevent damage to the parapharyngeal muscles, as well as avoiding activities that increase pharyngeal pressure, such as coughing, vomiting, sneezing, nose blowing, physical exertion, and post-extubation manual ventilation (20). The typical clinical finding is crepitation, but a CT-scan best detects extension of the emphysema. Differential diagnosis includes other causes of rapid-onset neck swelling, such as hemorrhage, hematoma and allergic reactions (17). Another important clinical condition, which should be taken into consideration as it has been infrequently described as a complication of tonsillectomy, is necrotizing fasciitis. Necrotizing fasciitis is soft-tissue infection characterized by rapidly progressing inflammation and necrosis of the subcutaneous fascial tissues. It has a particularly high mortality rate due to the proximity of many

vital anatomical structures. The lack of relevant risk factors, clinical signs of erythema, fever and painful swelling, as well as laboratory and radiological findings may help distinguish these two different pathologic conditions (63).

The treatment of manifested subcutaneous emphysema is usually conservative and includes a regular cardiopulmonary assessment and administration of broad-spectrum antibiotics. We consider the administration of antibiotics obligatory to prevent contamination and infection from the oral cavity. This is because cervical emphysema may be associated with bacteria spreading in the mediastinum or the development of cervical necrotizing fasciitis (64). Supplemental oxygen may facilitate absorption of nitrogen from air accumulating in the emphysematous cavity in a favorable downward concentration gradient (8). Avoiding pressure elevation can help to reduce the occurrence of emphysema following a tonsillectomy and the patient should be advised to avoid sneezing with a closed mouth, blowing the nose and other activities that can increase intrathoracic or intraoral pressure (e.g. the Valsalva maneuver). In this rationale, medications that suppress coughing and vomiting can be prescribed. In cases of respiratory failure, measures securing the airway by means of intubation or tracheostomy are favorable. In rare cases, a mediastinal expansion of the emphysema may require a thoracotomy. When the mucosal rupture is evident, a careful suture of the damaged mucosa is also advisable.

Despite mounting information regarding this subject, medical professionals must acknowledge important limitations of the data. Case reports and case series are classified as Level IV evidence according to the National Health and Medical Research Council system for assessing level of evidence (46), and thus are rarely conclusive. It should also be noted that in many records, not all details of the cases appear (e.g. the surgical method of tonsillectomy, or the exact nature of the conservative treatment), making this systematic review of case reports more a case-series study offering material for future observational or experimental studies.

Conclusion

Subcutaneous emphysema is a rare but potentially life-threatening complication of

tonsillectomy. The medical community should be aware of this complication. A follow-up of the patient and appropriate cooperation between anesthesiologists and surgeons can help prevent this complication progressing.

Acknowledgments

Mr. Petros Saravakos, Electrical and Computer Engineer, Software and Computer Analyst, M.Sc., designed Figure 6.

References

1. Kendrick D, Gibbin K. An audit of the complications of paediatric tonsillectomy, adenoidectomy and adenotonsillectomy. *Clin Otolaryngol Allied Sci.* 1993;18(2):115-7.
2. Mistry D, Kelly G. Consent for tonsillectomy. *Clin Otolaryngol Allied Sci.* 2004;29(4):362-8.
3. Leong SC, Karkos PD, Papouliakos SM, Apostolidou MT. Unusual complications of tonsillectomy: a systematic review. *Am J Otolaryngol.* 2007;28(6):419-22.
4. Randall DA, Hoffer ME. Complications of tonsillectomy and adenoidectomy. *Otolaryngol Head Neck Surg.* 1998;118(1):61-8.
5. Gillot C, Tombu S, Crestani V, Huvelle P, Moreau P. Subcutaneous emphysema and mediastinitis: unusual complications of tonsillectomy. *B-ENT.* 2005;1(4):197-200.
6. Hung MH, Shih PY, Yang YM, Lan JY, Fan SZ, Jeng CS. Cervicofacial subcutaneous emphysema following tonsillectomy: implications for anesthesiologists. *Acta Anaesthesiol Taiwan.* 2009;47(3):134-7.
7. Panerari AC, Soter AC, Silva FL, Oliveira LF, Neves MD, Cedin AC. Onset of subcutaneous emphysema and pneumomediastinum after tonsillectomy: a case report. *Braz J Otorhinolaryngol.* 2005;71(1):94-6.
8. Al Jabr I, Al Harethy S. Cervicofacial subcutaneous emphysema, a rare complication of tonsillectomy. *Egyptian Journal of Ear, Nose, Throat and Allied Sciences.* 2014;15(1):49-51.
9. Al Omari B, Sadacharam M, Sheahan P. Cervical surgical emphysema following routine tonsillectomy. *Rev Laryngol Otol Rhinol (Bord).* 2011;132(4-5):241-3.
10. Al-Layla AM, Al-Barzangi B, Badran I. Surgical Emphysema after Tonsillectomy in Jordan University Hospital. *J Med J.* 2009;43(1):51-4.
11. Andersen BR. Subcutaneous emphysema; a complication of tonsillectomy. *AMA Arch Otolaryngol.* 1958;68(6):697-9.
12. Bizaki A, Kaariainen J, Harju T, Rautiainen M. Facial subcutaneous emphysema after tonsillectomy. *Head Face Med.* 2014;10:11.

13. Braverman I, Rosenmann E, Elidan J. Closed Rhinolalia as a Symptom of Pneumomediastinum after Tonsillectomy: A Case Report and Literature Review. *Otolaryngol Head Neck Surg.* 1997; 116(4): 551-3.
14. Durchholz C, Passau., Wollin C, Metzler R. [Pneumomediastinum nach tonsillektomie]. *Chirurgische Praxis.* 2011;73(4):643-6.
15. Fechner FP, Kieff D. Cervical emphysema complicating tonsillectomy with argon beam coagulation. *Laryngoscope.* 2003;113(5):920-1.
16. Giussan AO, Savilova EI. [Subcutaneous emphysema of the face and neck following tonsillectomy and adenotomy]. *Vestn Otorinolaringol.* 1986(4):77-8.
17. Hampton SM, Cinnamond MJ. Subcutaneous emphysema as a complication of tonsillectomy. *J Laryngol Otol.* 1997;111(11):1077-8.
18. Kim JP, Park JJ, Kang HS, Song MS. Subcutaneous emphysema and pneumomediastinum after tonsillectomy. *Am J Otolaryngol.* 2010; 31(3): 212-5.
19. Koukoutsis G, Balatsouras DG, Ganelis P, Fassolis A, Moukos A, Katotomichelakis M, et al. Subcutaneous emphysema and pneumomediastinum after tonsillectomy. *Case Rep Otolaryngol.* 2013;154857.
20. Lima WL, Correa NS, de Campos JL, Navarro PM, Correia Lde O. Subcutaneous emphysema after tonsillectomy: case report. *Rev Bras Anesthesiol.* 2005;55(4):441-4.
21. Lopez Gonzalez MA, Mata Maderuelo F, Abrante Jimenez A, Lopez Palomo J, Soldado Patino L, Delgado Moreno F. [Subcutaneous emphysema and pneumomediastinum after tonsillectomy and adenoidectomy]. *Acta Otorrinolaringol Esp.* 1997;48(1):65-8.
22. Luk'ianenko VT, Bol'shakov VI, Kniazhanskii ES. [Emphysema of the floor of the mouth after a tonsillectomy]. *Vestn Otorinolaringol.* 1978(6):74-5.
23. Marioni G, De Filippis C, Tregnaghi A, Gaio E, Staffieri A. Cervical emphysema and pneumomediastinum after tonsillectomy: it can happen. *Otolaryngol Head Neck Surg.* 2003; 128(2): 298-300.
24. McGreevy EJ, McGreevy JV. Subcutaneous emphysema following tonsillectomy. *SD J Med Pharm.* 1957;10(5):160-1; passim.
25. Melgaard KR. Subcutaneous Emphysema after Tonsillectomy. *Acta Oto-Laryngologica.* 2009; 34(1): 95-7.
26. Miman MC, Ozturan O, Durmus M, Kalcioğlu MT, Gedik E. Cervical subcutaneous emphysema: an unusual complication of adenotonsillectomy. *Paediatr Anaesth.* 2001;11(4):491-3.
27. Nishino H, Kenmochi M, Kasugai S, Okada T, Ohashi T. Subcutaneous emphysema secondary to tonsillectomy: a case report. *Auris Nasus Larynx.* 2003;30 Suppl:S135-6.
28. Patel N, Brookes G. Surgical emphysema following tonsillectomy. *Ear Nose Throat J.* 2005; 84(10):660-1.
29. Piotrowski S, Jesikiewicz D. Mediastinal emphysema as a complication of the tonsilloadenotomy in child [Odma śródpiersiowa jako powikłanie tonsiloadenotomii u dziecka]. *Otolaryngologia Polska.* 2009;63(6):528-31.
30. Pratt LW, Hornberger HR, Moore VJ. Mediastinal emphysema complicating tonsillectomy and adenoidectomy. *Ann Otol Rhinol Laryngol.* 1962;71:158-69.
31. Prupas HM, Fordham SD. Emphysema secondary to tonsillectomy. *Laryngoscope.* 1977; 87(7): 1134-6.
32. Randrup TS, Rokkjær MS. Subkutant emfysem efter tonsillektomi. *Ugeskrift for Laeger.* 2012; 174(34):1904-5.
33. Rous J, Slipka J, Cermak Z. [An unusual early complication of tonsillectomy]. *Cesk Otolaryngol.* 1990;39(5):307-12.
34. Ruiz Gomez JM, Lorenzo Rojas J, Cortes Sanchez P, Ayala Martinez L. [Emphysema in the tonsil surgery. A case report]. *Acta Otorrinolaringol Esp.* 1998;49(4):321-3.
35. Sachdeva K. Subcutaneous Emphysema Complicating Tonsillectomy. *World Articles in Ear, Nose and Throat.* 2013;6(1).
36. Shine NP, Sader C, Coates H. Cervicofacial emphysema and pneumomediastinum following pediatric adenotonsillectomy: a rare complication. *Int J Pediatr Otorhinolaryngol.* 2005;69(11): 1579-82.
37. Siedek V, Betz CS, Leunig A. [Cervical skin emphysema: a rare complication following tonsillectomy]. *HNO.* 2007;55(2):121-4.
38. Stewart AE, Brewster DF, Bernstein PE. Subcutaneous emphysema and pneumomediastinum complicating tonsillectomy. *Arch Otolaryngol Head Neck Surg.* 2004;130(11):1324-7.
39. Tanaka K, Sigyrou H, Hokunan K, Yoshida C. Subcutaneous emphysema and pneumomediastinitis secondary to tonsillectomy. *Practica Otologica.* 2000; 93(1):39-42.
40. Tran DD, Littlefield PD. Late presentation of subcutaneous emphysema and pneumomediastinum following elective tonsillectomy. *Am J Otolaryngol.* 2015;36(2):299-302.
41. Wahid FI, Hamza A, Khan Q, Rehman HU, Ahmad I. Complications of tonsillectomy experienced at lady reading hospital peshawar. *Pakistan Journal of Medical and Health Sciences.* 2011; 5(4):771-4.
42. Watanabe K, Kunitomo M, Yamauchi Y, Kimura M, Masuno S, Aoki H, et al. Subcutaneous

emphysema after tonsillectomy: a case report. *J Nippon Med Sch.* 2004;71(2):111-3.

43. Yelnoorkar S, Issing W. Cervicofacial Surgical Emphysema following Tonsillectomy. *Case Rep Otolaryngol.* 2014;2014:746152.
44. Zivkovic D. [Subcutaneous emphysema of the face as a complication of tonsillectomy]. *Vopr Klin Lecheniia Zlokachestvennykh Novoobraz.* 1960; 17: 703-5.
45. Randrup TS, Rokkjaer MS. [Subcutaneous emphysema after adenotonsillectomy]. *Ugeskr Laeger.* 2012;174(34):1904-5.
46. Merlin T, Weston A, Toohar R. Extending an evidence hierarchy to include topics other than treatment: revising the Australian 'levels of evidence'. *BMC Med Res Methodol.* 2009;9:34.
47. Villagra Siles EJ, Rodriguez Perales MA, Garcia Mendoza A, Zaiden Torrez A. [Cervical emphysema after tonsillectomy. A case report]. *Acta Otorrinolaringol Esp.* 2006;57(5):251-2.
48. Tanaka K, Sigyou H, Hokunan K, Yoshida C. Subcutaneous emphysema and pneumomediastinitis secondary to tonsillectomy. *Practica Otologica.* 2000; 93(1):39-42.
49. Ferguson CC, Mc GP, Beckman IH, Broder M. Surgical emphysema complicating tonsillectomy and dental extraction. *Can Med Assoc J.* 1955; 72(11): 847-8.
50. Knutson RC, Ouellette AJ. Subcutaneous emphysema following tonsillectomy and adenoidectomy. *Minn Med.* 1954;37(12):877-9.
51. Kazantseva KS. [Subcutaneous emphysema of the neck following tonsillectomy]. *Vestn Otorinolaringol.* 1953;15(4):83.
52. Silverman JJ, Talbot TJ, McClean RW. Mediastinal Emphysema Following Tonsillectomy. *Diseases of the Chest.* 1953;23(4):397-402.
53. Tezel EB. [A case with unusual complications after tonsillectomy]. *Istanbul Tip Fak Mecmuasi.* 1952;15(1):97-100.
54. Baker LJ. Subcutaneous Emphysema Complicating Tonsillectomy. *Can Med Assoc J.* 1936; 34(6):670-1.
55. von Hofe FH. Emphysema of the Head and Neck Complicating Tonsillectomy. *JAMA: The Journal of the American Medical Association.* 1930; 95(13): 934.
56. Stein S. Surgical Emphysema Following Tonsillectomy. *The Laryngoscope.* 1923; 33(10): 785-7.
57. Rosenbaum C. Subcutaneous Emphysema Following Tonsillectomy. *JAMA: The Journal of the American Medical Association.* 1924;82(26):2119.
58. Chiu CL, Ong GS. Subcutaneous emphysema and pneumomediastinum after endotracheal anaesthesia. *Ann Acad Med Singapore.* 2000; 29(2): 256-8.
59. Podoshin L, Persico M, Fradis M. Posttonsillectomy emphysema. *Ear Nose Throat J.* 1979; 58(1):73-6, 81-2.
60. Ross HM, Grant FJ, Wilson RS, Burt ME. Nonoperative management of tracheal laceration during endotracheal intubation. *Ann Thorac Surg.* 1997; 63(1):240-2.
61. Grillo HC. Tracheal and Bronchial Trauma. In: Grillo HC, editor. *Surgery of the Trachea and Bronchi.* Lewiston: BC Decker; 2004. p. 274-5.
62. Janfaza P, Fabian R. Pharynx. In: Janfaza P, Nadol B, Galla R, Fabian R, Montgomery W, editors. *Surgical Anatomy of the Head and Neck* Cambridge, Massachusetts and London, England: Harvard University Press; 2011. p. 368-81.
63. Wolf H, Rusan M, Lambertsen K, Ovesen T. Necrotizing fasciitis of the head and neck. *Head Neck.* 2010;32(12):1592-6.
64. Sonne JE, Kim SB, Frank DK. Cervical necrotizing fasciitis as a complication of tonsillectomy. *Otolaryngol Head Neck Surg.* 2001;125(6):670-2.