

*Case Report*

## Vocal Cord Actinomycosis: A Case Report

\*Bijan Khademi<sup>1</sup>, Seyed-Hossein Dastgheib-Hosseini<sup>2</sup>, Mohammad-Javad Ashraf<sup>3</sup>

### **Abstract**

#### **Introduction:**

Actinomycosis is a systemic chronic bacterial infection caused by *Actinomyces Israelii*, an anaerobic organism normally resident in the human mouth. However, the actinomycosis of the larynx is very rare, and only about 15 cases have been reported in the literature so far. Most of the cases reported occurred in patients who had previously undergone radiotherapy for laryngeal cancer.

#### **Case Report:**

Here we report a case of actinomycosis of the larynx in a 14-year-old shepherd boy who was not immunocompromised but had a history of tooth extraction two months prior to admission to the hospital and severe laryngitis one year prior to admission.

#### **Conclusion:**

Laryngeal actinomycosis might be related to poor oral hygiene and mucosal barrier disruption, as well as to being immunocompromised.

#### **Keywords:**

*Actinomyces Israelii*, Laryngitis, Laryngeal actinomycosis, Vocal cord

Received date: 6 Jan 2011

Accepted date: 1 Mar 2011

<sup>1</sup>Department of otolaryngology, Shiraz Institute for Cancer Research, Shiraz University of Medical Sciences, Shiraz, Iran

<sup>2</sup>Department of otolaryngology, Shiraz University of Medical Sciences, Shiraz, Iran

<sup>3</sup>Department of pathology, Shiraz University of Medical Sciences, Shiraz, Iran

#### **\*Corresponding author:**

Department of otolaryngology, Khalili Hospital, Shiraz University of Medical Sciences, Shiraz, Iran

Email: khademib@yahoo.com, Fax: +98711647 14782

### Introduction

Actinomycosis may cause a chronic, suppurative infection which presents itself as cervicofacial, thoracic or abdominal lesions. Approximately 55% of actinomycosis is in the cervicofacial form.

*Actinomyces* species are an important component of the normal flora of the oropharynx. The disease occurs in healthy individuals as well as in immunocompromised patients, and should not be considered an opportunistic infection, even though the pathogenesis in many cases is believed to be tied to a break in the integrity of the mucosa that allows the organism to invade.

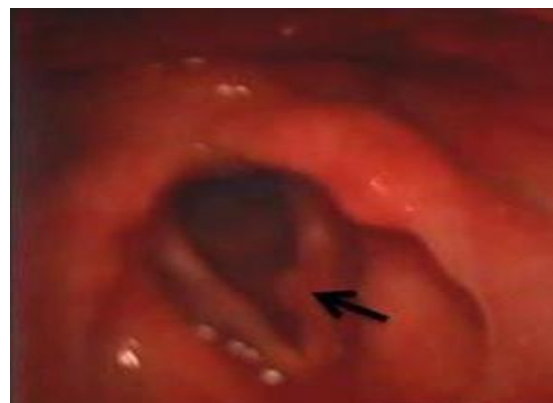Most of the cases reported occurred in patients who had previously undergone radiotherapy for laryngeal cancer (1,2).

Nonetheless, here we present the case of a shepherd with laryngeal actinomycosis whose risk factors were a past history of severe laryngitis and poor dental hygiene.

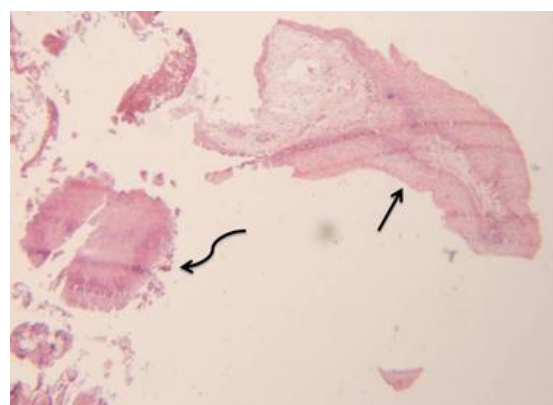
### Case Report

A 14-year-old Iranian shepherd boy was referred for two-month-long worsening vocal hoarseness. One year before admission, the patient had had a history of severe laryngitis following swimming in cold water. His parents claimed that since then, he had developed a harsh voice that persisted without change but that since two months prior to admission to the hospital, his hoarseness was progressively exacerbated. He had poor dental hygiene and also had a history of extraction of an infected tooth two months prior to admission to the hospital. Outpatient videostroboscopy revealed a nodule on the right vocal cord (Fig 1). Thus, under general anesthesia and direct laryngoscopy (DL), microsurgical removal of the nodule was performed. The pathological examination of the specimen revealed actinomycosis granules and granulomatous inflammatory reactions (Fig 2,3). The patient was treated with intravenous penicillin for two weeks followed by oral penicillin therapy for three months, and he

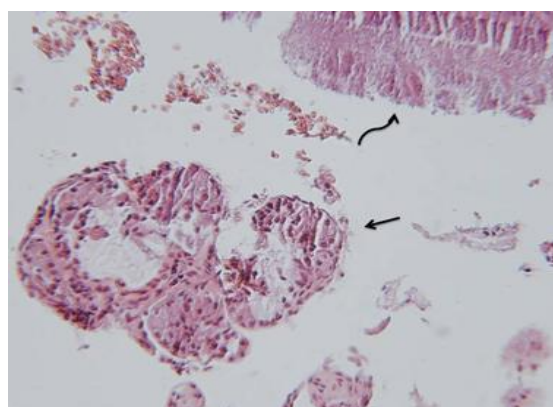
recovered fully. Indirect laryngoscopy (IL) four months and one year after the surgery confirmed complete healing with normal mucosal wave function and complete glottic closure.



**Fig1:** Rt side vocal cord nodule



**Fig 2:** Vocal cord squamousepithelium (upper right) and *actinomyces* colony (left) H&E stain (×100)



**Fig 3:** Filamentous and granular forms of *actinomyces* organism (upper right) associated with inflammatory cells and squamous epithelium, H&E stain (×250)

### Discussion

About 55% of all infections with *Actinomyces Israelii*, a gram-positive, filamentous, non-spore-forming bacterium previously thought to be a fungus, involve the head and neck.

*Actinomyces* also are typical inhabitants of the normal oral flora and can be isolated from various sites on the gingival crevices, tonsillar crypts, periodontal pocket and within various dental plaques. Cervical actinomycosis is believed to occur as the result of a break in the integrity of the mucosa that allows the *actinomyces* organism to infect deeper tissues. They develop more readily in patients who have undergone trauma, dental manipulation, and oral surgery and particularly in immunosuppressed, debilitated patients with poor oral hygiene, in whom this normal saprophyte of the oropharyngeal flora finds the conditions for pathological development.

Review of the literature reveals that actinomycosis of the larynx is often associated with an underlying history of squamous cell carcinoma of the larynx and therapeutic radiation therapy (1,2). In all these cases, authors believe that the postoperative or post-RT structural changes produce loss of physical and immunologic barriers and create an anaerobic condition which facilitates the development of actinomycotic infection by the oral cavity or pharyngeal entry.

An underlying history of SLE and immunosuppression after renal transplantation and laryngeal actinomycosis in patients without any underlying disease has also been reported (3,4).

In our case, laryngeal actinomycosis had developed in an immunocompetent shepherd boy without having had major surgical intervention. He had poor dental hygiene and had been in the vicinity of animals; therefore, actinomycosis was probably the normal flora of his oral cavity. Further, he had a history of

laryngitis that had caused a persistent harsh voice. As a result, his laryngitis had probably disrupted the normal mucosal barrier, was the probable cause of the nodule formation and had produced a good environment for the harboring and growth of actinomycosis.

In our case, the diagnosis was made by microscopic examination of the operative specimen. Several authors consider microscopic examination the quickest and the most sensitive way of diagnosis (1).

Moreover, the culture results helped approximately in 20% of all cases (5). It is important to know that *actinomyces* is a strict anaerobe and the laboratory should be notified if actinomycosis is suspected so that the culture can be held for at least two weeks.

Treatment modalities for treating actinomycosis typically include surgical intervention and medical antimicrobial administration. In our case, the surgical excision of the nodule may have been an important factor in its complete resolution. The recommended medical treatment is based on long-term administration of penicillin and/or, particularly in case of allergy or resistant strains, clindamycin for at least 2-6 months depending on the patient response.

### Conclusion

In conclusion, actinomycosis should be taken into consideration in the differential diagnosis of a large vocal cord nodule and might be related to poor oral hygiene and mucosal barrier disruption as well as to being immunocompromised. The diagnosis and treatment can be made by microsurgical removal of the nodule, having it examined at a pathology lab and an adequate period of antimicrobial treatment and the close monitoring of the patient's recovery subsequent to the commencement of therapy.

**References**

1. Syed MA, Ayshford CA, Uppal HS, Cullen RJ. Actinomycosis of the post-cricoid space: An unusual case of dysphagia. *J Laryngol Otol* 2001; 115(5): 428-9.
2. Nelson EG, Tybor AG. Actinomycosis of the larynx. *Ear Nose Throat J* 1992; 71(8): 356-8.
3. Sims HS, Heywood BB. Post-transplant actinomycosis of the posterior glottis involving both vocal processes. *Otolaryngol Head Neck Surg* 2007; 137(6): 967-8.
4. Sari M, Yazici M, Baglam T, Inanli S, Eren F. Actinomycosis of the larynx. *Acta Otolaryngol* 2007; 127(5): 550-2.
5. Hughes RA, Paonessa DF, Conway WF. Actinomycosis of the larynx. *Ann Otol Rhinol Laryngol* 1984; 93(5 Pt 1): 520.