

Intra-Operative Lymphatic Mapping and Sentinel Node Biopsy in Laryngeal Carcinoma: Preliminary Results

Ehsan Khadivi¹, Maryam Daghighi¹, Kamran Khazaeni¹, Vahid Reza Dabbagh Kakhki²,
Leili Zarifmahmoudi^{2,*}, Ramin Sadeghi²

Abstract

Introduction:

Sentinel node mapping has been used for laryngeal carcinoma in several studies, with excellent results thus far. In the current study, we report our preliminary results on sentinel node mapping in laryngeal carcinoma using intra-operative peri-tumoral injection of a radiotracer.

Materials and Methods:

Patients with biopsy-proven squamous cell carcinoma of the larynx were included in the study. Two mCi/0.4 cc Tc-99m-phytate in four aliquots was injected on the day of surgery, after induction of anesthesia, in the sub-mucosal peri-tumoral location using a suspension laryngoscopy. After waiting for 10 minutes, a portable gamma probe was used to search for sentinel nodes. All patients underwent laryngectomy and modified radical bilateral neck dissection. All sentinel nodes and removed non-sentinel nodes were examined by hematoxylin and eosin (H&E) staining.

Results:

Ten patients with laryngeal carcinoma were included. At least one sentinel node could be detected in five patients (bilateral nodes in four patients). One patient had pathologically involved sentinel and non-sentinel nodes (no false-negative cases).

Conclusion:

Sentinel node mapping in laryngeal carcinoma is technically feasible using an intra-operative radiotracer injection. In order to evaluate the relationship of T-stage and the laterality of the tumor with accuracy, larger studies are needed.

Keywords:

Laryngeal, Larynx, Radiotracer, Sentinel, SCC, Squamous Cell Carcinoma.

Received date: 13 Jan 2015

Accepted date: 12 Feb 2015

¹Sinus and Surgical Endoscopic Research Center, Mashhad University of Medical Sciences, Mashhad, Iran.

²Nuclear Medicine Research Center, Mashhad University of Medical Sciences, Mashhad, Iran.

*Corresponding Author:

Nuclear Medicine Research Center, Mashhad University of Medical Sciences, Mashhad, Iran.

Tel: +985138012794, E-mail: sadeghir@mums.ac.ir; raminsadeghi1355@yahoo.com

Introduction

Sentinel node mapping is the standard method of regional lymph node staging in breast cancer and melanoma (1,2). In this technique, the first draining lymph node(s) in the lymphatic drainage path of a tumor are identified (usually by radiotracers or blue dyes). These are called the sentinel node(s). The pathological condition of the sentinel nodes is considered a surrogate of the regional lymph node condition. Using this technique, the morbidity of the regional lymph node condition can be avoided in regional lymph node negative patients (3).

The sentinel node mapping concept has also been used with various degrees of success in gynecological, urological, and gastrointestinal tumors (4-7). For cutaneous and mucosal head and neck squamous cell carcinoma (SCC), sentinel node mapping has also been used with a high detection rate and sensitivity (8,9). Laryngeal SCC is a head and neck malignancy with different propensity for regional lymph node involvement. Location of the tumor (supraglottic vs. glottic/subglottic) and T-stage of the tumor are the variables related to the frequency of regional lymph node involvement in laryngeal SCC (10,11). Recommendations for regional lymph node dissection differ in the medical literature: in T3–T4 stage glottic cancer and in T2–T4 supra or subglottic tumors, elective neck dissection for clinically cervical node negative patients is recommended (11,12). Less invasive methods for regional lymph node staging in laryngeal carcinoma can reduce the complications of regional lymph node dissection as well as decreasing the surgery time.

Sentinel node mapping has been used for laryngeal carcinoma in several studies, with excellent results thus far (13-15). In the current study, we report our preliminary results on sentinel node mapping in laryngeal carcinoma using an intra-operative peri-tumoral injection of the radiotracer.

Materials and Methods

Ten patients with biopsy-proven SCC of the larynx were included in the study. Patients had no history of neck treatment, including radiotherapy or previous surgery. All patients were cN0 on neck examination and/or para-clinical imaging. Any of the following signs on computed tomography (CT) imaging were considered exclusion criteria: nodes larger than 10 mm, central necrosis, non-oval shape of nodes, perinodal tissue enhancement.

On the day of surgery, after induction of anesthesia, 2 mCi/0.4 cc Tc-99m-phytate in four aliquots was injected in the sub-mucosal peri-tumoral location using a suspension laryngoscopy. After waiting for 10 minutes, sentinel nodes were searched for using a portable gamma probe (EURO PROBE, France). Any lymph node with more than a two-fold count rate as compared with the background was considered as sentinel node and harvested (Fig.1).

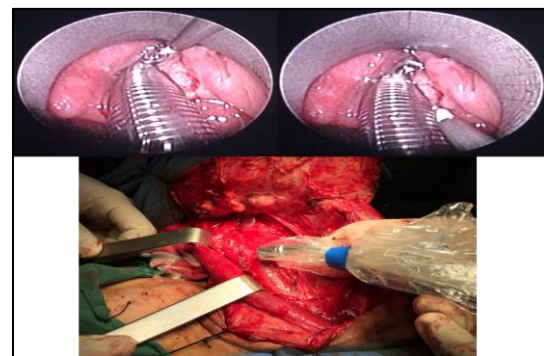


Fig.1: Intra-operative injection of the tracer and sentinel node mapping of a patient

After excision of the sentinel nodes, the background of the neck area was checked for any residual activity. The location of the sentinel nodes was recorded according to their anatomical levels in the neck. All patients underwent laryngectomy and modified radical bilateral neck dissection. All sentinel nodes and removed non-sentinel nodes were examined by H&E staining. For sentinel nodes, step sectioning was also performed in order not to miss any small metastasis.

Detection rate was defined as the ratio of patients with at least one detected sentinel node to all recruited patients. The false-negative rate was defined as the ratio of patients with involved neck lymph nodes without involved sentinel node to all patients with involved neck nodes and at least a harvested sentinel node. This study was approved by the local ethical committee of Mashhad University of Medical Sciences under the approval number 920275. All patients gave written informed consent before inclusion into the trial.

Results

Between May 2012 and Jan 2014, 10 patients with laryngeal SCC were included in the study. The mean age of the patients was 59.3 years (range: 48–69 years); nine

patients were male and one was female (F/M: 1/9). All patients had T3 laryngeal tumors except for patient No. 5 who presented with T2 supra-glottic tumor. At least one sentinel node could be detected in five patients, which was bilateral in four patients (detection rate: 5/10=50%). One-to-four sentinel nodes could be identified in these patients. The median number of detected sentinel nodes in the patients was 2. Neck dissection yielded 6–51 lymph nodes. The median number of dissected lymph nodes was 24. One patient had pathologically involved sentinel and non-sentinel nodes (no false-negative cases). No other patient had lymph node involvement on pathological examination. Characteristics of the patients are shown in (Table. 1).

Table 1: Characteristics of the patients and results of the lymph node mapping

Patient	Gender/age	Tumor location	T-stage	Number of sentinel nodes/number of harvested non-sentinel nodes	Location and laterality of sentinel nodes	Pathological sentinel node status	Pathological non-sentinel node status
1	F/62	Epiglottis+ AEF+ FVC+ TVC+ Arytenoid+ Ant commissure	3	3/37	II ipsi; II contra	-	-
2	M/69	Epiglottis+ AEF+ FVC+ TVC+ Arytenoid+ Ant & pos commissure + pyriform sinus	3	0/27	N/A	-	-
3	M/48	FVC+ TVC+ Arytenoid + Ant commissure	3	1/15	III ipsi	-	-
4	M/66	AEF+ FVC+ TVC+ Arytenoid + Ant commissure + sub-glottis	3	0/13	N/A	-	-
5	M/48	Epiglottis + AEF + FVC	2	4/51	II, III ipsi; II, III contra	-	-
6	M/55	Epiglottis + AEF + FVC + TVC + Arytenoid + Ant & pos commissure +sub-glottis	3	2/25	II ipsi; II contra	One contralateral sentinel node positive	One contralateral non-sentinel positive (location station III)
7	M/50	TVC + Ant commissure + Arytenoid + sub-glottis	3	0/24	N/A	-	-
8	M/62	TVC + Ant commissure with extension to the base of the epiglottis	3	0/6	N/A	-	-
9	M/58	FVC + TVC + Arytenoid + Ant commissure + sub-glottis	3	0/20	N/A	-	-
10	M/75	TVC + Ant commissure with extension to the base of the epiglottis	3	2/42	II ipsi; III contra	-	-

AEF: Aryepiglottic fold; FVC: False vocal chord; TVC: True vocal chord

Discussion

Sentinel node mapping is an important aspect of lymph node staging in several solid tumors of the head and neck, including melanoma, high risk SCC, and Merkel cell carcinoma (9,16,17).

Several authors have previously reported their experience of sentinel node mapping in laryngeal carcinoma (13,15,18-31). The characteristics of these studies can be found (in Table. 2).

Table 2: Characteristics of previous studies of sentinel node mapping in laryngeal carcinoma

Author/Year	Mapping material	Number of patients	Detection rate	Sensitivity
Cheng 2010	Combined blue dye and radiotracer	40	82% by tracer, 66% by blue dye	83.3%
Fang 2001	Blue dye	23	95.6%	100%
Werner 2005	Radiotracer	11	100%	100%
Li 2009	Radiotracer	33	90.9%	93.3%
Werner 2002	Radiotracer	13	100%	100%
Chone 2008	Radiotracer	5	100%	N/A
Lawson 2010	Radiotracer	29	100%	100%
Lopez Molla 2006	Radiotracer	19	89.47%	50%
Prgomet 2008	Radiotracer	15	100%	100%
Hoft 2004	Radiotracer	12	91.6%	N/A
Yoshimoto 2012	Radiotracer	16	100%	100%
Tomifuji 2008	Radiotracer	19	100%	100%
Werner 2002	Radiotracer	14	100%	100%
Flach 2013	Radiotracer	19	68.4%	80%
Werner 2004	Radiotracer	31	100%	100%
Dunne 2004	radiotracer	12	100%	100%

Our preliminary results showed that sentinel node mapping using an intra-operative radiotracer injection is feasible in laryngeal carcinoma patients. We achieved a 50% detection rate and no false-negative cases.

Tc-99m-phytate was used as the mapping material in this study as we have previously shown this to be a reliable tracer for sentinel node mapping (32). Intra-operative injection has also been used in several studies investigating different tumors (33) with excellent results as movement of the radiotracer around the lymphatic system is very fast and there is no need for a long wait after injection (34-37). As shown in Table 2, only two studies used blue dye as the mapping

material and the remaining groups used only radiotracers for sentinel node mapping. We did not use blue dye and only relied on radiotracers for lymphatic mapping due to logistic problems and the risk of life-threatening complications by blue dyes, as previously reported in the literature (38).

The sentinel node detection rate in our study was sub-optimal (50%) as compared with the previous studies shown in Table 2. This may be due to several reasons. First, the learning curve effect could play an important role, as previous studies showed that surgeons gradually gain experience in sentinel node mapping with improvement in the detection rate (39). Second, the extension of tumors in our

patient population was very wide and this could result in detection failure. As shown in Table 1, nine out of 10 included patients in our study had T3 tumors, while the other studies presented in Table 2 all recruited patients in the lower T-stages of T1 or T2. A higher T-stage increases the risk of lymphatic blockage, which invariably results in sentinel node detection failure (5,40,41). More patients are needed to further evaluate the relationship of T-stage and sentinel node detection failure in laryngeal carcinomas.

The larynx is a midline organ and can exhibit bilateral lymphatic drainage (20). This can have an important implication in sentinel node mapping. Midline tumors without bilateral detected sentinel nodes are a significant challenge for lymphatic mapping as this lymphatic pattern can result from lymph node involvement on one side with a higher risk of false-negative cases (42). Our results also showed that in four out of five patients with detected sentinel nodes, lymphatic drainage was bilateral. We need many more patients in order to evaluate the effect of laterality of lymphatic drainage on the accuracy of sentinel node mapping in laryngeal cancer.

Another important aspect of sentinel node mapping is false-negative cases. No false-negative cases were revealed in this study, which is compatible with the results of the previous studies mentioned in Table 2. However, the number of patients with pathologically involved nodes remains low, and larger studies are needed in order to evaluate the false-negative rate more efficiently.

Conclusion

Sentinel node mapping in laryngeal carcinoma is technically feasible using an intra-operative radiotracer injection. Larger studies are needed in order to evaluate the relationship of T-stage and the

laterality of the tumor with accuracy of the technique.

Acknowledgements

This study is the preliminary result of a residency thesis under the approval number 920275 and has been supported by the Vice Chancellery of Research of Mashhad University of Medical Sciences.

References

1. Javan H, Gholami H, Assadi M, Pakdel AF, Sadeghi R, Keshtgar M. The accuracy of sentinel node biopsy in breast cancer patients with the history of previous surgical biopsy of the primary lesion: systematic review and meta-analysis of the literature. *Eur J Surg Oncol* 2012;38 (2):95-109.
2. Mehrabibahar M, Forghani MN, Memar B, Jangjoo A, Dabbagh Kakhki VR, Zakavi SR, Aryana K, Abdollahi A, Sadeghi R. Sentinel lymph node biopsy in melanoma patients: An experience with Tc-99m antimony sulfide colloid. *Iran J Nucl Med* 2010;18 (1):1-6.
3. Krag DN, Weaver DL. Pathological and molecular assessment of sentinel lymph nodes in solid tumors. *Semin Oncol* 2002;29 (3):274-9.
4. Ansari M, Rad MA, Hassanzadeh M, Gholami H, Yousefi Z, Dabbagh VR, Sadeghi R. Sentinel node biopsy in endometrial cancer: systematic review and meta-analysis of the literature. *Eur J Gynaecol Oncol* 2013;34 (5):387-401.
5. Dabbagh Kakhki VR, Bagheri R, Tehranian S, Shojaei P, Gholami H, Sadeghi R, Krag DN. Accuracy of sentinel node biopsy in esophageal carcinoma: a systematic review and meta-analysis of the pertinent literature. *Surg Today* 2014;44 (4):607-19.
6. Hassanzade M, Attaran M, Treglia G, Yousefi Z, Sadeghi R. Lymphatic mapping and sentinel node biopsy in squamous cell carcinoma of the vulva: systematic review and meta-analysis of the literature. *Gynecol Oncol* 2013;130 (1):237-45.
7. Sadeghi R, Gholami H, Zakavi SR, Kakhki VR, Tabasi KT, Horenblas S. Accuracy of sentinel lymph node biopsy for inguinal lymph node staging of penile squamous cell carcinoma: systematic review and meta-analysis of the literature. *J Urol* 2012;187 (1):25-31.
8. Ahmed MM, Moore BA, Schmalbach CE. Utility of head and neck cutaneous squamous cell carcinoma sentinel node biopsy: a systematic review. *Otolaryngol Head Neck Surg* 2014;150 (2):180-7.

9. Thompson CF, St John MA, Lawson G, Grogan T, Elashoff D, Mendelsohn AH. Diagnostic value of sentinel lymph node biopsy in head and neck cancer: a meta-analysis. *Eur Arch Otorhinolaryngol* 2013;270 (7):2115-22.
10. Dias FL, Lima RA, Manfro G, Barbosa MM, Salviano S, Rocha RM, Marques AS, Cernea CR, Kligerman J. Management of the N0 neck in moderately advanced squamous carcinoma of the larynx. *Otolaryngol Head Neck Surg* 2009;141 (1):59-65.
11. Rodrigo JP, Cabanillas R, Franco V, Suarez C. Efficacy of routine bilateral neck dissection in the management of the N0 neck in T1-T2 unilateral supraglottic cancer. *Head Neck* 2006;28 (6):534-9.
12. Candela FC, Shah J, Jaques DP, Shah JP. Patterns of cervical node metastases from squamous carcinoma of the larynx. *Arch Otolaryngol Head Neck Surg* 1990;116 (4):432-5.
13. Flach GB, Bloemena E, van Schie A, Hoekstra OS, van Weert S, Leemans CR, de Bree R. Sentinel node identification in laryngeal cancer: Feasible in primary cancer with previously untreated neck. *Oral Oncol* 2013;49 (2):165-8.
14. Mielcarek-Kuchta D, Szyfter W, Manasterskil J, Kaczmarek J, Wojtowicz JG, Czepczynski R. [The sentinel node in cancer of the oral cavity, pharynx and larynx]. *Otolaryngol Pol* 2005;59 (5):683-8.
15. Werner JA, Dunne AA, Ramaswamy A, Folz BJ, Lippert BM, Moll R, Behr T. Sentinel node detection in N0 cancer of the pharynx and larynx. *Br J Cancer* 2002;87 (7):711-5.
16. Schmalbach CE, Bradford CR. Is sentinel lymph node biopsy the standard of care for cutaneous head and neck melanoma? *Laryngoscope* 2015;125 (1):153-60.
17. Sadeghi R, Adinehpour Z, Maleki M, Fallahi B, Giovanella L, Treglia G. Prognostic significance of sentinel lymph node mapping in Merkel cell carcinoma: systematic review and meta-analysis of prognostic studies. *Biomed Res Int* 2014;2014:489536.
18. Cheng Y, Wang BQ, Li SJ, Wen SX, Xia LJ, Li XF, Zhao DS. [A comparative study of sentinel lymph node detection in laryngeal and hypopharyngeal carcinoma by lymphoscintigraphy method and blue dye]. *Zhonghua Er Bi Yan Hou Tou Jing Wai Ke Za Zhi* 2010;45 (1):42-6.
19. Fang J, Wei X, Li S, Wang C, Tian A, Tao Y, Sun X, Zou S, Li M, Cai S, Luan X. [Clinical study of the sentinel lymph node of patients with laryngeal and hypopharyngeal carcinomas]. *Zhonghua Er Bi Yan Hou Ke Za Zhi* 2001;36 (4):244-6.
20. Werner JA, Dunne AA, Davis RK. Intraoperative lymphatic mapping in cases of midline squamous cell carcinoma. *Acta Otolaryngol* 2005;125 (4):403-8.
21. Li ZW, Hu GH, Lei CM, Zhong SX, Li B, Hong SL, Zhu J. [Localization of sentinel lymph node with radionuclide in clinically N0 laryngeal and hypopharyngeal cancers]. *Zhonghua Er Bi Yan Hou Tou Jing Wai Ke Za Zhi* 2009;44 (5):395-9.
22. Werner JA, Dunne AA, Ramaswamy A, Folz BJ, Brandt D, Kulkens C, Moll R, Lippert BM. Number and location of radiolabeled, intraoperatively identified sentinel nodes in 48 head and neck cancer patients with clinically staged N0 and N1 neck. *Eur Arch Otorhinolaryngol* 2002;259 (2):91-6.
23. Chone CT, Magalhes RS, Etchehebere E, Camargo E, Altemani A, Crespo AN. Predictive value of sentinel node biopsy in head and neck cancer. *Acta Otolaryngol* 2008;128 (8):920-4.
24. Lawson G, Matar N, Nollevaux MC, Jamart J, Krug B, Delos M, Remacle M, Borghet TV. Reliability of sentinel node technique in the treatment of N0 supraglottic laryngeal cancer. *Laryngoscope* 2010;120 (11):2213-7.
25. Prgomet D, Huic D, Mutvar A, Rakusic Z, Bilic M, Katic V. [Sentinel lymphadenectomy in squamous cell carcinoma of the pharynx and larynx]. *Lijec Vjesn* 2008;130 (3-4):58-61.
26. Lopez Molla C, Amoros Sebastia LI, Ferrer Ramirez MJ, Pla Mocholi A, Ourena M, Villanueva A, Lopez Martinez R. [Preliminary results of the relevance the sentinel node in head and neck tumors]. *Acta Otorrinolaringol Esp* 2003;54 (3):185-90.
27. Hoft S, Maune S, Muhle C, Brenner W, Czech N, Kampen WU, Janig U, Laudien M, Gottschlich S, Ambrosch P. Sentinel lymph-node biopsy in head and neck cancer. *Br J Cancer* 2004;91 (1):124-8.
28. Yoshimoto S, Hasegawa Y, Matsuzuka T, Shiotani A, Takahashi K, Kohno N, Yoshida T, Kitano H. Sentinel node biopsy for oral and laryngopharyngeal squamous cell carcinoma: a retrospective study of 177 patients in Japan. *Auris Nasus Larynx* 2012;39 (1):65-70.
29. Tomifuji M, Shiotani A, Fujii H, Araki K, Saito K, Inagaki K, Mukai M, Kitagawa Y, Ogawa K. Sentinel node concept in clinically n0 laryngeal and hypopharyngeal cancer. *Ann Surg Oncol* 2008;15 (9):2568-75.
30. Werner JA, Dunne AA, Ramaswamy A, Dalchow C, Behr T, Moll R, Folz BJ, Davis RK. The sentinel node concept in head and neck cancer: solution for the controversies in the N0 neck? *Head Neck* 2004;26 (7):603-11.

- 31.** Dunne AA, Folz BJ, Kuropkat C, Werner JA. Extent of surgical intervention in case of N0 neck in head and neck cancer patients: an analysis of data collection of 39 hospitals. *Eur Arch Otorhinolaryngol* 2004;261 (6):295-303.
- 32.** Dabbagh Kakhki VR, Jangjoo A, Tavassoli A, Asadi M, Sadri K, Fatahi Masoom A, Mehrabibahar M, Memar B, Ansari M, Sadeghi R. Sentinel node mapping for early breast cancer patients using ^{99m}Tc-phytate: Single center experience on 165 patients. *Iran J Nucl Med* 2012;20 (2):25-9.
- 33.** Bagheri R, Naghavi F, Kakhki VRD, Zakavi SR, Fattahi AS, Jafarian AH, Haghi SZ, Sadeghi R. Sentinel node mapping in esophageal squamous cell carcinoma using intra-operative combined blue dye and radiotracer techniques. *Esophagus* 2013;10 (4):211-6.
- 34.** Sadeghi R, Forghani MN, Memar B, Rajabi Mashhadi MT, Dabbagh Kakhki VR, Abdollahi A, Zakavi SR. How long the lymphoscintigraphy imaging should be continued for sentinel lymph node mapping? *Ann Nucl Med* 2009;23 (6):507-10.
- 35.** Abdollahi A, Jangjoo A, Dabbagh Kakhki VR, Rasoul Zakavi S, Memar B, Naser Forghani M, Mehrabibahar M, Sadeghi R. Factors affecting sentinel lymph node detection failure in breast cancer patients using intradermal injection of the tracer. *Rev Esp Med Nucl* 2010;29 (2):73-7.
- 36.** Jangjoo A, Forghani MN, Mehrabibahar M, Rezapana A, Kakhki VR, Zakavi SR, Ghavamnasiri MR, Kashani I, Hashemian F, Sadeghi R. Comparison of early and delayed lymphoscintigraphy images of early breast cancer patients undergoing sentinel node mapping. *Nucl Med Commun* 2010;31 (6):521-5.
- 37.** Aliakbarian M, Memar B, Jangjoo A, Zakavi SR, Reza Dabbagh Kakhki V, Aryana K, Forghani MN, Sadeghi R. Factors influencing the time of sentinel node visualization in breast cancer patients using intradermal injection of the radiotracer. *Am J Surg* 2011;202 (2):199-202.
- 38.** Jangjoo A, Forghani MN, Mehrabibahar M, Sadeghi R. Anaphylaxis reaction of a breast cancer patient to methylene blue during breast surgery with sentinel node mapping. *Acta Oncol* 2010;49 (6):877-8.
- 39.** Mansel RE, MacNeill F, Horgan K, Goyal A, Britten A, Townson J, Clarke D, Newcombe RG, Keshtgar M, Kissin M, Layer G, Hilson A, Ell P, Wishart G, Brown D, West N. Results of a national training programme in sentinel lymph node biopsy for breast cancer. *Br J Surg* 2013;100 (5):654-61.
- 40.** Straalman K, Kristoffersen US, Galatius H, Lanng C. Factors influencing sentinel lymph node identification failure in breast cancer surgery. *Breast* 2008;17 (2):167-71.
- 41.** Kadkhodayan S, Hasanzadeh M, Treglia G, Azad A, Yousefi Z, Zarifmahmoudi L, Sadeghi R. Sentinel node biopsy for lymph nodal staging of uterine cervix cancer: A systematic review and meta-analysis of the pertinent literature. *Eur J Surg Oncol* 2014; 41(1):1-20.
- 42.** Sadeghi R, Hasanzadeh M. Sentinel lymph node biopsy algorithm: can it be a universal method for midline tumors? *Gynecol Oncol* 2014;132 (2):273-4.