

Acoustic Neurinomas

*Mohammad FarajiRad¹, SanazFarajiRad², ElnazFarajiRad³

Abstract

Acoustic neuromas (AN) are schwann cell-derived tumors that commonly arise from the vestibular portion of the eighth cranial nerve also known as vestibular schwannoma(VS) causes unilateral hearing loss, tinnitus, vertigo and unsteadiness. In many cases, the tumor size may remain unchanged for many years following diagnosis, which is typically made by MRI. In the majority of cases the tumor is small, leaving the clinician and patient with the options of either serial scanning or active treatment by gamma knife radiosurgery (GKR) or microneurosurgery. Despite the vast number of published treatment reports, comparative studies are few. The predominant clinical endpoints of AN treatment include tumor control, facial nerve function and hearing preservation. Less focus has been put on symptom relief and health-related quality of life (QOL). It is uncertain if treating a small tumor leaves the patient with a better chance of obtaining relief from future hearing loss, vertigo or tinnitus than by observing it without treatment. In this paper we review the literature for the natural course, the treatment alternatives and the results of AN. Finally, we present our experience with a management strategy applied for more than 30 years.

Keywords:

Acoustic neuromas, Acoustic schwannoma, Brain tumor, Vestibular schwannoma, Vestibular neurilemmomas

Received date: 29Jul 2010

Accepted date: 14Dec 2010

¹Department of neurosurgery, Mashhad university of Medical Sciences, Mashhad, Iran

²Department of neurology, Mashhad university of Medical Sciences, Mashhad, Iran

³Medical student, Mashhad university of Medical Sciences, Mashhad, Iran

*Corresponding author:

Ghaem Hospital, Mashhad University of Medical Sciences, Mashhad, Iran

Email: farajim@mu ms.ac.ir

Tel: +985118012615

Introduction

Acoustic neuromas (AN) are schwann cell-derived tumors that commonly arise from the vestibular portion of the eighth cranial nerve also known as Vestibular Schwannomas, acoustic schwannomas, or vestibular neurilemmomas (1). AN account for approximately 8 percent of intracranial tumors in adults and 80 to 90 percent of tumors of the cerebellopontine angle (CPA). In comparison, they are rare in children, except for those with neurofibromatosis (2). Surgical treatment of AN has been one of the most challenging procedures of neurosurgical practice for more than a century. In 1894 Charles Ballance was probably the first surgeon to remove aAN, and in the surgical report he described the difficulties of getting his index finger around the tumor to achieve removal. The patient was alive twelve years later although with fifth and seventh nerve palsies. Concerned about the high morbidity and mortality of early AN surgery, Cushing advocated intracapsular tumor debulking. As standards of neurosurgery and anaesthesiology improved, the concept of total tumor removal was reintroduced by Dandy (2). The epidemiology, clinical presentation, diagnosis, and treatment of AN will be reviewed here.

Epidemiology

The overall incidence of AN is about one per 100,000 person-years. However, the incidence appears to be increasing, probably due at least in part to the incidental diagnosis of asymptomatic lesions with the widespread use of magnetic resonance imaging (MRI) and computed tomography (CT) (1,2). As an example, a retrospective analysis of 46,000 MRI scans done for other reasons identified eight unsuspected AN (0.02 percent) (2), and autopsy studies suggest that the prevalence may be even higher (3). The median age at diagnosis is approximately 50 years (4). The tumors

are unilateral in more than 90 percent of cases (5), affecting the right and left sides with equal frequency. Bilateral AN are primarily limited to patients with autosomal dominant neurofibromatosis type 2 (4-6).

Risk Factors

Risk factors associated with the development of AN include the following: Exposure to loud noise, either in the workplace or from loud music, (7-9). Experimental studies of tissue injury and repair following acoustic trauma support the biological plausibility of this association (10-11). Neurofibromatosis type 2 (NF2) have schwannomas. NF2 is typically characterized by bilateral AN and/or a family history of NF2. Childhood exposure to low-dose radiation for benign conditions of the head and neck (12).

Patients with a history of parathyroid adenoma the reason for this association is unclear (13).

Some but not all studies have shown an increased incidence of various brain tumors, including AN, associated with the use of cellular telephones.

Histopathology

AN arise from perineural elements of the Schwann cell in the affected nerve and are similar pathologically to peripheral schwannomas found in other parts of the body. They occur with equal frequency on the superior and inferior branches of the vestibular nerve; only rarely are they derived from the cochlear portion of the VIII nerve (14).

Microscopically, zones of alternately dense and sparse cellularity, called Antoni A and B areas respectively, are characteristic of AN. Malignant degeneration is extremely rare with only six cases having been reported. Immunohistochemical staining for S100 protein is usually positive in both the

benign and the rare malignant forms of this tumor (15).

Clinical Presentation

Symptoms associated with AN can be due to cranial nerve involvement, cerebellar compression, or tumor progression.

The clinical presentations of these tumors are illustrated by a series of 1000 AN reported by Samii(16). Clinical manifestations in this series included the following:

Cochlear Nerve

Symptomatic cochlear nerve involvement occurred in 95 percent of patients. The two major symptoms were hearing loss and tinnitus. Hearing loss was present in 95 percent but only two-thirds of these patients were aware of this limitation. The hearing loss was usually chronic, with an average duration of about four years. Occasionally, AN can present with sudden sensorineural hearing loss.

Tinnitus: was present in 63 percent with an average duration of three years. The incidence of tinnitus was higher in hearing than in deaf patients but was also present in 46 percent of deaf patients.

Vestibular nerve: Involvement of the vestibular nerve occurred in 61 percent of patients. The most nondescript vertiginous sensations, such as brief tilting or veering, can suggest the presence of a AN.

Trigeminal nerve: Trigeminal nerve disturbances occurred in 17 percent of patients. The most common symptoms were facial numbness (paresthesia), hypesthesia, and pain.

Facial nerve: The facial nerve was involved in 6 percent of patients. The primary symptoms were facial paresis and, less often, taste disturbances.

Tumor progression: Other presenting signs can be the result of tumor progression such as ataxia, Brainstem compression, cerebellar tonsil herniation, hydrocephalus and death can occur in untreated cases. The functions of the lower cranial nerves

can also become impaired, leading to dysarthria, dysphagia, aspiration, and hoarseness (16).

Diagnosis

The diagnosis of AN is generally suggested by the presence of asymmetric sensorineural hearing loss or other cranial nerve deficits. Such symptoms are followed by MRI or CT (17).

The differential diagnosis includes meningioma, which accounts for 4 to 10 percent of cases. Other less common causes of such lesions include facial nerve schwannomas, gliomas, cholesterol cysts, cholesteatomas(epidermoid), hemangiomas, aneurysms, arachnoid cysts, lipomas, and metastatic tumor (18).

Physical Examination

Hearing tests are abnormal due to involvement of the acoustic nerve. The Weber and Rinne tests may be useful in suggesting asymmetric sensorineural hearing impairment.

A decreased or absent ipsilateral corneal reflex and facial twitching or hypesthesia may occur as cranial nerves V and VII become affected. Other cranial nerve deficits are uncommon unless the tumor is large. Romberg, Hall-Pike, and other common office balance tests are typically normal.

Audiometry

Audiometry is the best initial screening laboratory test for the diagnosis of AN, since only 5 percent of patients will have a normal test. Pure tone and speech audiometry should be performed in an acoustically shielded area. Test results typically show an asymmetric sensorineural hearing loss, usually more prominent in the higher frequencies. Hearing loss does not necessarily correlate with tumor size. The speech discrimination score is usually markedly reduced in the affected ear and out of proportion to the measured hearing loss.

Many other auditory tests have been used historically to try to diagnose AN. These include acoustic reflex testing, impedance audiometry, and Bekesy audiometry. They have limited accuracy and diagnostic value, and their utility has diminished with the advent of brainstem-evoked response audiometry (AER/ABR).

Brainstem-evoked response audiometry can be used as a further screening measure in patients with unexplained asymmetries in standard audiometric testing. Prior to magnetic resonance imaging (MRI), ABR was the most accurate screening modality (19).

Vestibular Testing

Vestibular testing has limited utility as a screening test for the diagnosis of AN because of the accuracy of evoked response audiometry.

Imaging

The procedure of choice is magnetic resonance imaging (MRI), which can detect tumors as small as 1 to 2 mm in diameter (20). When brainstem testing is abnormal or the suspicion for a AN is high for another reason, MRI scanning with gadolinium contrast should be performed, including millimeter sections through the internal auditory meatus.

ANs are seen on MRI and CT scans as enhancing lesions in the region of the internal auditory canal with variable extension into the cerebellopontine angle. CT scans with bone windows can also be of prognostic significance as the extent of widening of the IAC and the extent of tumor growth anterior and caudal to the IAC are predictive of postoperative hearing loss (21-25).

Fast spin echo MRI may be useful as a screening test due to its low cost compared to gadolinium MRI, noninvasiveness, and high sensitivity and specificity. In one study of 25 patients and 50 ears, there were 11 true positives and 39 true negatives on gadolinium MRI. There were

no false positives or false negatives with fast spin echo MRI (26). This test is useful when performed specifically for evaluation for a AN, not as a general screen.

Treatment

Patient management is influenced by the natural history of AN, as well as the overall condition of the patient. The three major treatment options are surgery, radiation therapy, and observation.

Natural History

AN have a variable natural history. Serial imaging studies have shown that the average growth rate is 2 mm/year (27), but rates as high as 25 mm/year have been described in a few patients (28).

Surgery

Surgery usually results in cure of AN, with only rare recurrences following total resection. There are three standard operative approaches:

Retromastoidsuboccipital (retrosigmoid)

Translabyrinthine

Middle fossa

Selection of a particular approach is determined by the size of the tumor and whether hearing preservation is being attempted. The suboccipital approach can be used for any size tumor with or without attempted hearing preservation. The translabyrinthine approach has been recommended for acoustic tumors larger than 3 cm and for smaller tumors when hearing preservation is not an issue (29). The middle fossa approach is suitable for small (<1.5 cm) tumors when hearing preservation is a goal.

In many institutions, a team consisting of a neurosurgeon and an otologist perform the procedure. The experience of both the surgeon and the hospital are important in optimizing the surgical outcome and minimizing the risk of complications (30). With technologic advances, operative mortality is minimal for this nonmalignant but potentially fatal tumor.

Surgical morbidity, which includes hearing loss, facial weakness, and vestibular disturbances, depends upon tumor size. Facial nerve function can be preserved in most patients even with large tumors (31-33), and serviceable hearing can be preserved in many patients. However, only rarely does hearing improve after AN surgery. Intraoperative facial nerve and auditory monitoring have alerted surgeons to potential injury, thereby improving the final outcome (34). Persistent headaches are another significant complication following surgery (35-36). Postoperative headaches were more commonly associated with the retrosigmoid surgical approach, and tended to be more frequent and severe in women.

The outcome is less favorable in patients who undergo subtotal removal in an attempt to preserve anatomical continuity of the facial or acoustic nerves. Regrowth and/or recurrence, which are usually asymptomatic, occur in up to 15 percent (37-38).

Radiation Therapy

Radiation therapy approaches that have been used in patients with AN include stereotactic radiosurgery, stereotactic radiotherapy, and proton beam therapy.

Stereotactic Radiosurgery

Stereotactic radiosurgery (SRS) is a technique that utilizes multiple convergent beams to deliver a high single dose of radiation to a radiographically discrete treatment volume, thereby minimizing injury to adjacent structures. This can be accomplished with either the gamma knife or a linear accelerator. Radiosurgery is a viable treatment option for selected patients with smaller tumors (<3 cm) or for enlarging tumors in patients who are not candidates for surgery.

There is a concern that scarring following SRS may complicate subsequent microsurgery should the tumor recur. In a series of 20 cases in which surgical salvage was performed following

recurrence after radiosurgery, approximately one-half were determined to have greater difficulty for resection or facial nerve preservation (39).

AN in patients with neurofibromatosis type 2 (NF2) present a particular challenge because lesions are frequently bilateral (41). Although these patients have a higher risk of hearing loss than those without NF2, SRS represents an important alternative to conventional surgery (42).

The risk of further decrease in auditory acuity secondary to SRS and the role of radiation dose and toxicity is discussed in detail elsewhere.

Stereotactic Radiotherapy

Fractionated stereotactic radiotherapy (SRT), utilizes focused doses of radiation given over a series of treatment sessions. The intent is to reduce radiation injury to critical neural structures while preserving tumor control.

Multiple series have demonstrated the safety and efficacy of this approach (43-45).

Proton Beam Therapy

Proton beam therapy may provide maximal local tumor control while minimizing cranial nerve injuries. The physical characteristics of the beam result in the majority of the energy being deposited at the end of a linear track (the Bragg peak), with the dose falling rapidly to zero beyond the Bragg peak. Thus, the use of proton beam therapy permits the delivery of high doses of RT to the target volume while limiting the "scatter" dose received by surrounding tissues.

Observation

Since ANs are typically slow growing, observation with follow-up MRI scans every 6 to 12 months may be warranted in carefully selected patients.

A review of the literature identified 21 studies that included 1345 patients who were managed conservatively (43). With an average follow-up of 3.2 years, 43

percent of tumors showed evidence of growth, 51 percent remained stable, while 6 percent had evidence of regression without treatment. Hearing loss occurred in one-half of the 347 individuals in whom it was assessed longitudinally. In 15 of the studies, 20 percent of 1001 individuals eventually required treatment with either surgery or radiation, due to either tumor growth on imaging or symptom progression.

Observation may be particularly appropriate in elderly patients who are poor candidates for immediate intervention. However, if there are signs or symptoms of tumor progression, age should not be considered a contraindication to surgery or an indicator of adverse prognosis (44-45). In one series of 61 elderly patients, for example, complete removal was achieved in all but two, there was no mortality, and the facial nerve and hearing were preserved in 95 and 41 percent, respectively.

Observation is associated with a risk of progressive hearing loss. If hearing preservation is an important consideration, early treatment should be encouraged.

Observation is contraindicated in patients with large tumors and brainstem compression or hydrocephalus.

Post Treatment Followup

Because of the potentially slow growth of these tumors, prolonged follow-up is necessary. The following represents an empiric approach.

For patients being managed with observation, yearly scans for 10 years,

with scans subsequently every three to five years if there has been no growth.

For patients who underwent surgery, yearly scans for 8 to 10 years, and less frequently thereafter if no residual tumor is present.

For patients treated with RT, yearly scans for 10 years and then every two years if no growth seen.

Conclusion

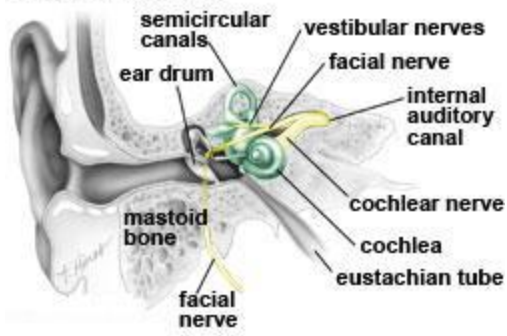
Acoustic neuromas account (AN) for 80 to 90 percent of cerebellopontine angle tumors (CPAs) in adults. The most common clinical manifestations of AN are unilateral sensorineural hearing loss, often in association with tinnitus. Symptoms may also be due to involvement of other cranial nerves. Diagnosis of a CPA tumor is based upon MRI or CT imaging.

For patients with large tumors, young age, or significant hearing impairment, we suggest early rather than delayed therapeutic intervention.

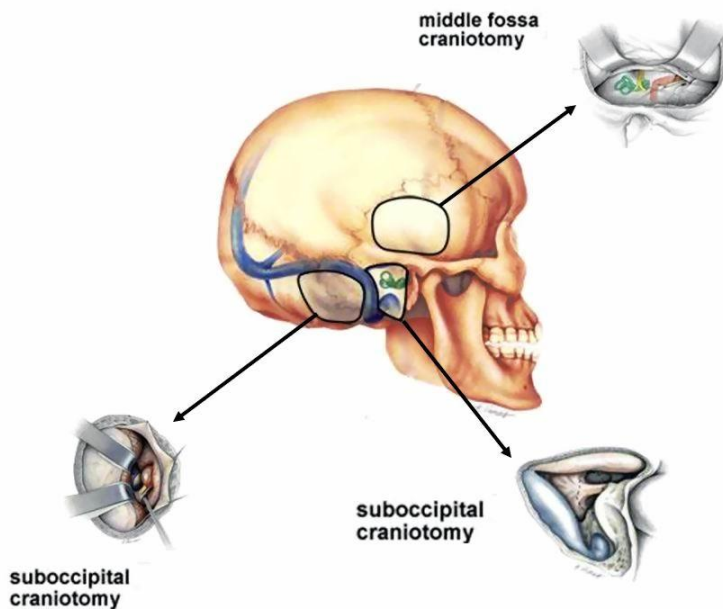
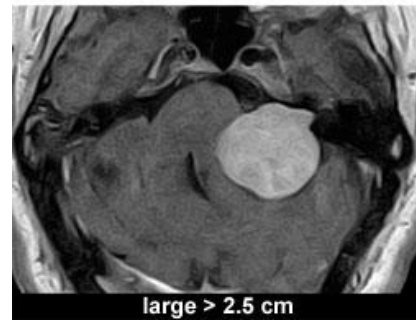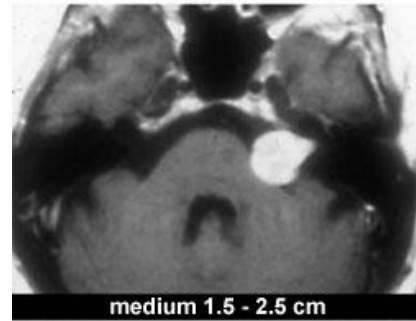
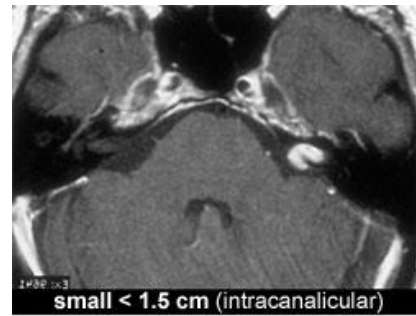
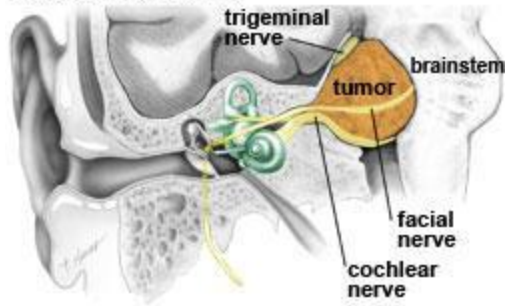
Both surgery and various radiation therapy techniques represent acceptable options for patients undergoing treatment. The choice of therapy should be based upon the availability of teams with appropriate expertise in treating AN, as well as patient preferences.

For older patients with small tumors and limited hearing loss, we suggest observation with serial imaging and audiometry. Such patients should be monitored for evidence of tumor progression.

A. normal anatomy



B. acoustic neuroma



References

1. Lin D, Hegarty JL, Fischbein NJ, Jackler RK. The prevalence of incidental acoustic neuroma. *Arch Otolaryngol Head Neck Surg* 2005; 131: 241.
2. Faraji M, Hermans B, Samii M. Hemifacial spasm: A report of 100 cases treated by microvascular decompression. *Medical J Isl Rep Iran* 1991; 5(1-2): 15-8.
3. Tos M, Stangerup SE, Caye-Thomasen, P. What is the real incidence of vestibular schwannoma? *Arch Otolaryngol Head Neck Surg* 2004; 130: 216.
4. Edwards, CG, Schwartzbaum, JA, Lonn, S. Exposure to loud noise and risk of acoustic neuroma. *Am J Epidemiol* 2006; 163: 327.
5. Preston-Martin S, Thomas DC, Wright WE, Henderson BE. Noise trauma in the etiology of acoustic neuromas in men in Los Angeles County, 1978-85. *Br J Cancer* 1989; 59: 783.
6. Preston-Martin S, Mack WJ. Neoplasms of the nervous system. In: *Cancer epidemiology and prevention*. Shottenfeld D, Fraumeni JF. (editors). 2nded. New York: Oxford University Press; 1996.
7. Ryals BM, Rubel EW. Hair cell regeneration after acoustic trauma in adult *Coturnix* quail. *Science* 1988; 240: 1774.
8. Faraji M. [Computed tomography in intracranial space occupying lesions]. Mashhad: Mashhad University of Medical Sciences; 2002. (Persian)
9. Faraji-Rad M, Vahedi P. Cerebrospinal fluid shunt complications. *J Neurosurgery* 2005; 15(1): 1-4.
10. Schneider AB, Ron E, Lubin J. Acoustic neuromas following childhood radiation treatment for benign conditions of the head and neck. *Neuro Oncol* 2008; 10: 73.
11. Faraji M, Mokhtari N. [Neurinoma of glossopharyngeal nerve]. *Iranian journal of otorhinolaryngology* 2005; 17(1): 18-22. (Persian)
12. Backlund LM, Grander D, Brandt L. Parathyroid adenoma and primary CNS tumors. *Int J Cancer* 2005; 113: 866.
13. Matthies C, Samii M. Management of 1000 AN(acoustic neuromas): Clinical presentation. *Neurosurgery* 1997; 40: 1.
14. Lunsford LD, Niranjan A, Flickinger JC. Radiosurgery of vestibular schwannomas: Summary of experience in 829 cases. *J Neurosurg* 2005; 102: 195-9.
15. Wilson DF, Hodgson RS, Gustafson MF. The sensitivity of auditory brainstem response testing in small acoustic neuromas (see comments). *Laryngoscope* 1992; 102: 961.
16. Samii M, Matthies C, Krebs S. Management of AN (acoustic neuromas): Radiological features in 202 cases-their value for diagnosis and their predictive importance. *Neurosurgery* 1997; 40: 469.
17. Marx SV, Langman AW, Crane RC. Accuracy of fast spin echo magnetic resonance imaging in the diagnosis of vestibular schwannoma. *Am J Otolaryngol* 1999; 20: 211.
18. Fucci MJ, Buchman CA, Brackmann DE, Berliner KI. Acoustic tumor growth: Implications for treatment choices. *Am J Otol* 1999; 20: 495.
19. Faraji-Rad M. [Trigeminal neuralgia and epidermoid tumor]. *Iranian journal of otorhinolaryngology* 1994; 6(3-4): 50-6. (Persian)
20. Lanman TH, Brackmann DE, Hitselberger WE, Subin B. Report of 190 consecutive cases of large acoustic tumors (vestibular schwannoma) removed via the translabyrinthine approach. *J Neurosurg* 1999; 90: 617.
21. Barker FG, Carter BS, Ojemann RG. Surgical excision of acoustic neuroma: Patient outcome and provider caseload. *Laryngoscope* 2003; 113: 1332.
22. Samii M, Matthies C. Management of 1000 AN (acoustic neuromas): Surgical management and results with an emphasis on complications and how to avoid them. *Neurosurgery* 1997; 40: 11.

23. Darrouzet V, Martel J, Enee V. Vestibular schwannoma surgery outcomes: Our multidisciplinary experience in 400 cases over 17 years. *Laryngoscope* 2004; 114: 681.
24. Samii M, Matthies C. Management of 1000 AN (acoustic neuromas): The facial nerve-preservation and restitution of function. *Neurosurgery* 1997; 40: 684.
25. Anderson DE, Leonetti J, Wind JJ. Resection of large vestibular schwannomas: Facial nerve preservation in the context of surgical approach and patient-assessed outcome. *J Neurosurg* 2005; 102: 643.
26. Ryzenman JM, Pensak ML, Tew JM. Headache: A quality of life analysis in a cohort of 1,657 patients undergoing acoustic neuroma surgery, results from the acoustic neuroma association. *Laryngoscope* 2005; 115: 703.
27. Schankin CJ, Gall C, Straube A. Headache syndromes after acoustic neuroma surgery and their implications for quality of life. *Cephalalgia* 2009; 29: 760.
28. Cerullo L, Grutsch J, Osterdock R. Recurrence of vestibular (acoustic) schwannomas in surgical patients where preservation of facial and cochlear nerve is the priority. *Br J Neurosurg* 1998; 12: 547.
29. Lunsford LD, Niranjan A, Flickinger JC. Radiosurgery of vestibular schwannomas: Summary of experience in 829 cases. *J Neurosurg* 2005; 102 Suppl: 195.
30. Faraji-Rad M, Abbasiun K, Rahmat H. [Epidermis tumors (A report of 31 cases)]. *Journal of medical council of Islamic Republic of Iran* 1990; 10(2): 127-31. (Persian)
31. Shin M, Ueki K, Kurita H, Kirino T. Malignant transformation of a vestibular schwannoma after gamma knife radiosurgery. *Lancet* 2002; 360: 309.
32. Chopra R, Kondziolka D, Niranjan A. Long-term follow-up of acoustic schwannoma radiosurgery with marginal tumor doses of 12 to 13. *Gyn Int J Radiat Oncol Biol Phys* 2007; 68: 845.
33. Roche PH, Regis J, Deveze A. (Surgical removal of unilateral after failed gamma knife radiosurgery). *Neurochirurgie* 2004; 50: 383.
34. Subach BR, Kondziolka D, Lunsford LD. Stereotactic radiosurgery in the management of acoustic neuromas associated with neurofibromatosis Type 2. *J Neurosurg* 1999; 90: 815.
35. Ito K, Shin M, Matsuzaki M. Risk factors for neurological complications after acoustic neurinoma radiosurgery: Refinement from further experiences. *Int J Radiat Oncol Biol Phys* 2000; 48: 75.
36. Phi JH, Kim DG, Chung HT. Radiosurgical treatment of AN in patients with neurofibromatosis type 2: Tumor control and hearing preservation. *Cancer* 2009; 115: 390.
37. Combs SE, Welzel T, Schulz-Ertner D. Differences in clinical results after LINAC-based single-dose radiosurgery versus fractionated stereotactic radiotherapy for patients with vestibular schwannomas. *Int J Radiat Oncol Biol Phys* 2010; 76: 193.
38. Williams JA. Fractionated stereotactic radiotherapy for acoustic neuromas. *Int J Radiat Oncol Biol Phys* 2002; 54: 500.
39. Koh ES, Millar BA, Menard C. Fractionated stereotactic radiotherapy for acoustic neuroma: single-institution experience at the princess margaret hospital. *Cancer* 2007; 109: 1203.
40. Andrews DW, Suarez O, Goldman HW. Stereotactic radiosurgery and fractionated stereotactic radiotherapy for the treatment of acoustic schwannomas: Comparative observations of 125 patients treated at one institution. *Int J Radiat Oncol Biol Phys* 2001; 50: 1265.
41. Weber DC, Chan AW, Bussiere MR. Proton beam radiosurgery for vestibular schwannoma: tumor control and cranial nerve toxicity. *Neurosurgery* 2003; 53: 577.
42. Bakkouri WE, Kania RE, Guichard JP. Conservative management of 386 cases of unilateral vestibular schwannoma: Tumor growth and consequences for treatment. *J Neurosurg* 2009; 110: 662.

43. Smouha EE, Yoo M, Mohr K, Davis RP. Conservative management of acoustic neuroma: A meta-analysis and proposed treatment algorithm. *Laryngoscope* 2005; 115: 450.
44. Pulec JL. Acoustic neuroma surgery in geriatric patients. *Ear Nose Throat J* 1999; 78:429.
45. Samii M, Tatagiba M, Matthies C. Acoustic neurinoma in the elderly: Factors predictive of postoperative outcome. *Neurosurgery* 1992; 31: 615.