

Mixed Pyolaryngocele: A Rare Case of Deep Neck Infection

*Rachid Mahdoufi¹, Ismail Barhmi¹, Nabil Tazi¹, Redallah Abada¹,
Mohamed Roubal¹, Mohamed Mahtar¹

Abstract:

Introduction:

Pyolaryngocele is a very rare and serious complication of laryngocele. It can present as deep neck space infection and mislead the diagnosis. Our aim is to bring this unusual entity to the attention of surgeons and describe its clinical features.

Case Report:

We report a case of a 45-year-old male patient with a five-week history of neck swelling, dysphonia, dyspnea and odynophagia. An urgent CT scan showed a mixed pyolaryngocele. The management consisted of a high dose antibiotic and an excision of the residual laryngocele via an external approach.

Conclusion:

A pyolaryngocele is an unusual complication of laryngocele, which becomes secondarily infected, causing many symptoms. Removing the laryngocele is still the best treatment option to prevent this complication and recurrence.

Keywords:

Laryngocele, Larynx, Management, Pyolaryngocele.

Received date: 21 Jan 2016

Accepted date: 3 Aug 2016

¹Department of Otorhinolaryngology-Head and Neck Surgery, Service d'ORL-CCF, Hospital 20 Aout 1953, CHU IBN ROCHD, Casablanca, Maroc.

Corresponding Author:

Service d'ORL et chirurgie cervico-faciale, Hospital 20 Aout 1953, 6 Rue Lahssen ELAARJOUN, 20360, Casablanca, Maroc.

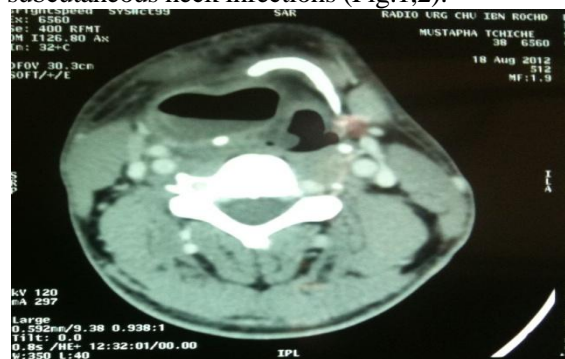Tel: +212663466994, E-mail: mahdoufir@gmail.com

Introduction

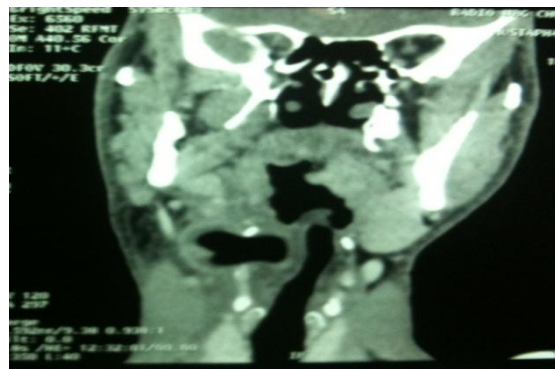
Laryngocele is an abnormal dilatation or herniation of the laryngeal saccule forming an air sac. It may be asymptomatic in a majority of patients, but it can also compromise speech, feeding and respiration because of its compressive symptoms. When this cavity is filled with pus it is called laryngopyocele or pyolaryngocele. This paper attempts to describe a mixed or combined pyolaryngocele and its medical and surgical management, in addition to a review of the most recent literature.

Case Report

A 45-year-old male presented with a 3-day history of acute neck pain, radiating to the right ear, and fever. He also suffered from a sore throat, progressive hoarseness, and odynophagia with slow-growth cervical tumefaction in the right submandibular region. Symptoms like dyspnea or high dysphagia were absent. The patient had no significant medical history or predisposing risk factors. ENT examination revealed a diffuse, tender swelling in the upper part of the neck on the right side at level III region, covered with skin erythema and few crepitus. The patient was admitted in the emergency department for a deep space neck infection. A fine needle aspiration assessment was performed on the neck swelling. This produced air with 15ml of frank pus that was submitted for microscopy, culture and sensitivity testing. A course of high-dose intravenous Metronidazole and Ceftriaxone was commenced. An urgent CT scan of the neck showed a large right-sided combined pyolaryngocele associated with regional and subcutaneous neck infections (Fig.1,2).



Figs 1: A computed tomography scan revealed a cystic lesion with a hydroaeric level in the axial images, An intra-extra laryngeal component on the right side with extension through the thyrohyoid membrane of 5 cm × 3 cm × 2.5 cm, which could be determined in the coronal sections.



Figs 2: A computed tomography scan revealed a cystic lesion with a hydroaeric level in the axial images, with airway collapse, compatible with a superinfected mixed laryngocele, associated with emphysema in the deep planes of the neck.

Intravenous antibiotic therapy was continued for one week. After the condition of the patient improved steadily, direct laryngoscopy confirmed that a smooth swelling, originating in the right ventricle, was partially obscuring the ipsilateral vocal cord and the laryngeal lumen and was causing a limited obstruction.

Surgical resection of the laryngocele was performed under general anesthesia by the external lateral cervical approach.

The histopathological report confirmed the diagnosis of laryngocele. The postoperative period was uneventful and the healthy patient was discharged 5 days after surgery. Six months after surgery, a follow-up examination was conducted and it was observed that the patient had completely recovered. The patient was asymptomatic with no swelling or infection on the neck and no bulging in the larynx.

Discussion

An excessive dilatation of the laryngeal saccule forms a laryngocele (1). The etiology is unknown and unclear (2). The congenital theory suggests that there is an abnormal growth of the saccule (long saccule) during the normal development of the larynx. However, it has been suggested to arise in people with prolonged periods of continuous increased laryngeal pressure such as glass blowers and wind instrument players (3,4). In our patient, there is no well-known etiology, thus it may be difficult to find the etiology of an acquired laryngocele. Laryngoceles may extend internally (20%) into the airway or externally (30%) through the

thyrohyoid membrane. Therefore, they may present as internal, external or combined mixed internal and external laryngocele (50%) (5).

Laryngoceles are usually asymptomatic. It appears and produces symptoms only as it enlarges or when it becomes infected. The symptoms depend on the type and size of the mass. The main symptoms, upon presentation, are variable and non specific; such as airway obstruction, increasing stridor, hoarseness, sore throat, cough, pain, snoring, globus sensation or a visible or palpable mass in the neck (1,6- 8).

Very rarely, an estimated 8% of laryngoceles, as reported in the literature, can become infected, fill with pus, and turn into a laryngopyocele (9). Similarly, in our patient's case, a mixed laryngopyocele will present with an infected neck mass with a very unstable airway and can be a vital emergency. In severe cases, urgent management including tracheostomy could be required.

CT scan has proved to be the golden standard imaging method in the diagnosis of different types of laryngoceles. Additionally, the differential diagnosis is usually made with a CT scan (10,11).

In addition to coexisting with a deep neck infection or potential upper airway obstruction, the association of a laryngocele with laryngeal carcinoma should not be underestimated. Pathological studies of resected laryngeal carcinomas have revealed up to 18% containing laryngoceles (12). Therefore, care must be taken to rule out malignancy and appropriate tests must be performed.

The conservative treatment of symptomatic pyolaryngocele has been described in literature (13). However, in our case, the patient was managed with urgent securing of the airways, administration of broad-spectrum antibiotics and steroids, and aspiration of purulent material to decompress the sac. At a later stage, after relieving the acute symptoms, we performed an external approach with a formal excision of the laryngocele.

Conclusion

Laryngopyoceles are a rare complication of laryngoceles. They can present with serious complaints like dyspnea and sepsis. They should be kept in mind during the differential

diagnosis of upper deep neck infection with hoarseness and odynophagia.

In our opinion, the present case is of particular interest since the patient was affected by a complicated laryngocele unrelated to his symptoms. It is mandatory, vis-à-vis this clinical presentation, to make an emergency CT scan in order to establish an accurate diagnosis and begin appropriate treatment to avoid an undesirable evolution.

In our patient, the laryngocele was not associated with laryngeal cancer, but it is most important to remember and to consider the possibility of this association.

We advocate for the external resection of laryngopyoceles in emergency situations. This allowed for an adequate exposure of the lesion, in addition to a post-operative recovery that was free from complications.

According to our point of view, endoscopic laser treatment would not have permitted complete excision of this large and mixed (external and internal) lesion.

References

1. Akbas Y, Unal M, Pata YS. Asymptomatic bilateral mixedtype laryngocele and laryngeal carcinoma. *Eur Arch Otorhinolaryngol* 2004; 261: 307-9.
2. Erdogmus B, Yazici B, Ozturk O, Ataoglu S, Yazici S. Laryngocele in association with ankylosing spondylitis. *Wien Klin Wochenschr* 2005; 117: 718-20.
3. M. Amin, A. G. D.Maran. "The aetiology of laryngocele". *Clinical Otolaryngology and Allied Sciences* 1988; 13(4): 267-72.
4. P. H. Ward. "Bilateral laryngoceles in a young trumpet player: case report". *Ear, Nose and Throat Journal* 2001; 80(3):132.
5. Dray TG, Waugh PF, Hillel AD. The association of laryngoceles with ventricular phonation. *J Voice* 2000; 14:278-81.
6. Lancella A, Abbate G, Dosdegani R. Mixed laryngocele: a case report and review of the literature. *Acta Otorhinolaryngol Ital* 2007; 27(5): 255-7.
7. Upile T, Jerjes W, Sipaul F, El Maaytah M, Singh S, Howard D, et al. Laryngocele: a rare complication of surgical tracheostomy. *BMC Surg*. 2006; 27;6(1):14-5.
8. Fraser L, Pittore B, Frampton S, Brennan P, Puxeddu R. Laryngeal debridement: an alternative treatment for a laryngopyocele presenting with severe airway obstruction. *Acta Otorhinolaryngol Ital*. 2011; 31(2):113-7.

9. Cassano L, Lombardo P, Marchese-Ragona R, Pastore A. Laryngopyocele: three new clinical cases and review of the literature. *The European Archives of Oto-Rhino-Laryngology* 2000; 257(9): 507–11.

10. Vasileiadis I, Kapetanakis S, Petousis A, Stavrianaki A, Fiska A, Karakostas E. Internal laryngopyocele as a cause of acute airway obstruction: an extremely rare case and review of the literature. *Acta Otorhinolaryngol Ital* 2012; 32(1):58-62.

11. Nazaroglu H, Ozates M, Uyar A, Deger E, Simsek M. Laryngopyocele: signs on computed tomography. *Eur J Radiol* 2000; 33(1):63-5.

12. Micheau C, Luboinski B, Lanchi P, Cachin Y. Relationship between laryngoceles and laryngeal carcinomas. *Laryngoscope* 1978; 88(6):680-8.

13. Ling F, Lamothe A. Is there a role for conservative management for symptomatic laryngopyocele? Case report and literature review. *J. Otolaryngol* 2004; 33(4):264–8.