

Association of Deviated Nasal Septum as an Etiological Factor for Antrochoanal Polyp

Sreelakshmi Muraleedharan¹, *Marina Saldanha¹, Shibin Samson², Raghuraj Uppoor²

Abstract

Introduction:

The etiology of Antrochoanal polyp (ACP) has been a subject of controversy. A deviated nasal septum may contribute to ACP formation by forcing a maxillary cyst through the accessory ostium. This study aims to evaluate the role of DNS in the formation of ACP.

Materials and Methods:

This retrospective case-control study included 40 diagnosed ACP cases (Group A) and 40 asymptomatic controls (Group B). The imaging scans of 80 patients were retrieved from the database and reviewed to correlate septal deviation with ACP using three septal deviation classifications- Mladina classification, classification based on the location of most prominent point of septal deviation and Baumann classification.

Results:

In Group A, septal deviation was present in 92.5% of patients, with 55% showing left-sided ACP with left DNS and 37.5% right-sided ACP with right DNS. In the control group, septal deviation was present in 90% of patients. On comparing septal deviation and ACP using Mladina classification (p value = 0.098) and Baumann classification (p value=0.805), no statistical significance was observed. A statistically significant difference (p value <0.001) was observed between the cases and control groups based on the classification of the location of most prominent point of septal deviation.

Conclusion:

In the present study, we were unable to establish a definitive causality between deviated nasal septum and the occurrence of an Antrochoanal polyp. However, deviation of the nasal septum between the anterior and posterior ends of the middle turbinate may act as a contributory factor in the formation of ACP.

Keywords: Antrochoanal Polyp, Baumann Classification, Computed Tomography, Deviated Nasal Septum, Mladina Classification

Received date: 27 Apr 2025

Accepted date: 04 Jan 2026

**Please cite this article:* Muraleedharan S, Saldanha M, Samson S, Uppoor R. Association of Deviated Nasal Septum as an Etiological Factor for Antrochoanal Polyp. *Iran J Otorhinolaryngol.* 2026;38(2):93-98.

Doi: 10.22038/ijorl.2026.86472.3898


¹Department of Otorhinolaryngology, NITTE (Deemed to be University), KS Hegde Medical Academy, Mangalore, India.

²Department of Radiodiagnosis, NITTE (Deemed to be University), KS Hegde Medical Academy, Mangalore, India.

*Corresponding author:

Department of Otorhinolaryngology, NITTE (Deemed to be University), KS Hegde Medical Academy.

E-mail: saldanhamarina@gmail.com

 Copyright©2026 Mashhad University of Medical Sciences. This work is licensed under a Creative Commons Attribution-Noncommercial 4.0 International License <https://creativecommons.org/licenses/by-nc/4.0/deed.en>

Introduction

In 1906, Gustav Killian described Antrochoanal Polyp (ACP) in his study "The origin of Choanal polypi," as beginning in the maxillary sinus mucosa, extending out of the accessory ostium into the middle meatus and proceeding posteriorly to the choana and nasopharynx (1,2).

Earlier studies in the literature reported that the Dutch anatomist Fredrik Ruysch reported two cases of nasal polyps developing in the Highmore antrum in 1691 (3) and an emergence of a polyp from the maxillary sinus and leaving the accessory ostium by Zuckerkandl from Graz in 1891 (4). Brown Kelly in 1909 showed that there was an association between antral cyst and wide accessory ostium (5). Additionally, it has also been proposed that acinar mucous gland blockage brought on by persistent phlogosis (allergic or infectious) may be the source of the cystic portion formation of ACP. The etiology of ACP has always been a matter of debate, with various theories having been put forth. Possible causes include allergies, chronic inflammation, vaso-motor imbalance, sensitivity to aspirin, epithelium rupture, and cystic fibrosis (6,7). Anatomical features such as septal deviation or spur can result in higher pressure levels that can result in herniation of an intramural cyst through an accessory ostium, leading to the formation of an ACP (26,8). The aim of our study was to correlate the laterality of deviated nasal septum as an etiological factor for ACP.

Materials and Methods

This was a retrospective case-control study conducted in the Department of Otorhinolaryngology in Justice KS Hegde Charitable Hospital, Mangalore, India. Ethical clearance was obtained from the Institutional Ethics Committee (IEC NO: INST. EC/ EC/ 254/ 2023). The medical records over a period of 2 years from 2021-2023 were collected from the Medical Records Department using code j33.8 and j33.9. This study included 80 patients who were divided into two groups – Group A (case) included 40 patients who were diagnosed clinically, radiologically and confirmed histopathologically as a case of ACP, and Group B (control) included 40 patients who presented with complaints of headache without any nasal symptoms and underwent Computed Tomography scan of Nose and PNS. Patients who had a history of previous turbinate surgery and revision cases of ACP were excluded from the study.

The imaging of all the patients was retrieved from database. The software RISPACS was used for evaluation by two independent radiologists to assess the degree and laterality of septal deviation using three different classification systems for septal deviation - Mladina classification of deviated nasal septum (9), classification based on location of most prominent point of deviation (10) and Baumann classification of deviated nasal septum and correlated with the side of ACP (11). (Table 1)

Table 1. Classification Systems of septal deviations

Classification I	Mladina classification of septal deviation
Type I	Septal Tilt deformity of nasal Septum
Type II	Deviation in the form of letter 'C' in Anteroposterior direction
Type III	Deviation in the form of letter 'C' in Cephalocaudal direction
Type IV	Deviation in the form of letter 'S' in Anteroposterior direction
Type V	Deviation in the form of letter 'S' in Cephalocaudal direction
Type VI	Nasal septum with localized deviations or spurs
Classification II	Based on location of most prominent point of Septal Deviation
Type I	Caudal Deviation is placed in the nasal septal region in front of the head of inferior turbinate
Type II	Anterior deviation is located in the nasal septal region between anterior edges of inferior turbinate and middle turbinate
Type III	Medial Deviation occur in the nasal septal region between anterior and posterior edge of the middle turbinate
Classification III	Baumann Classification of septal deviation
Type I	Septal crest with ipsilateral vomeral spur
Type II	Cartilaginous deviated nose with ipsilateral subluxation / contralateral vertical septal deviation
Type III	High Septal deviation with contralateral septal crest
Type IV	Caudally inclined septum with contralateral subluxation/ ipsilateral vertical septal deviation/ipsilateral septal crest/ ipsilateral vomeral spur
Type V	Septal crest with contralateral vomeral spur
Type VI	Caudally inclined septum with contralateral subluxation / ipsilateral vertical septal deviation/ contralateral septal crest/ contralateral vomeral spur

The data was analysed using SPSS version 20 software. Fisher’s Exact test was done, and p-value less than 0.05 was considered statistically significant.

Results

In Group A, out of 40 cases, 15 were males, and 25 were females. In Group B out of 40 controls, 16 were males and 24 were females.

In Group A, 92.5% (n=37) patients had septal deviation, 55% (n=22) patients had left ACP with DNS to left, 37.5% (n=15) patients had right ACP with DNS to right, indicating that the ACP formation was on the same side as that of the septal deviation. 7.5 % (n=3) of patients did not have septal deviation, with 5% (n=2) patients having right ACP and 2.5% (n=1) left ACP (Fig.1)

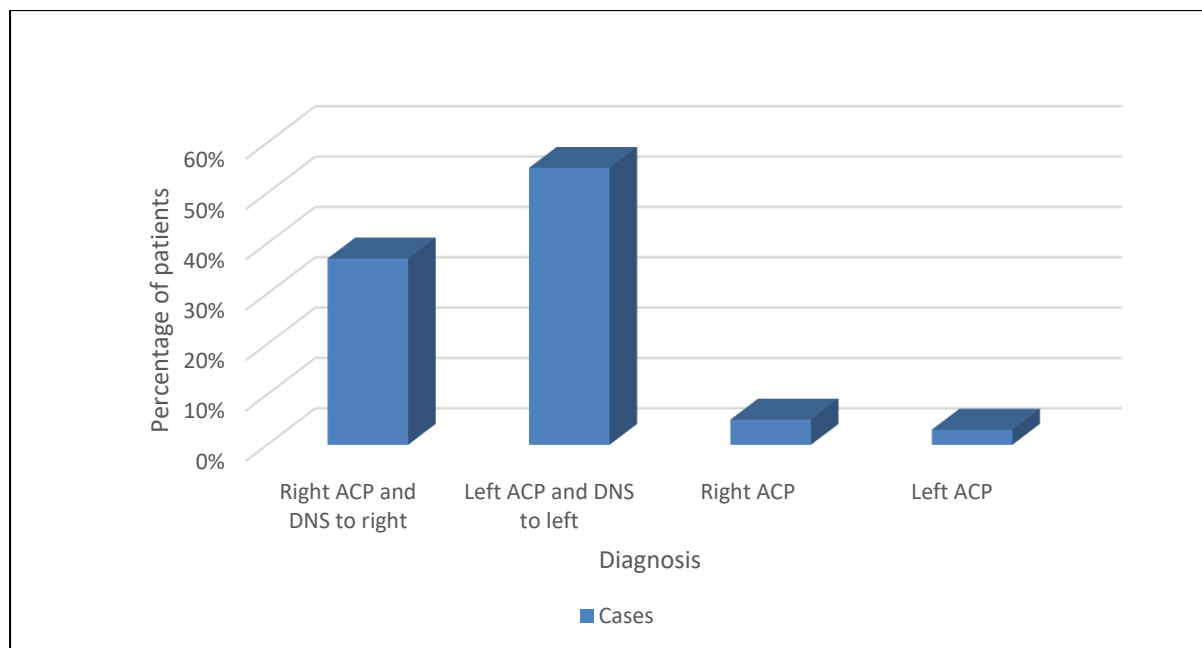


Fig 1. Percentage of patients with ACP and deviation of nasal septum

Percentage of patients with ACP and deviation of the nasal septum.

In the control group, 10% (n=4) of patients did not have any septal deviation. Out of 90% (n=36) patients who had septal deviation, 62.5% (n=25) were diagnosed with migraine and 37.5% (n=15) had other causes of headache. Computed Tomography scans did not show any features of sinusitis.

Comparison Based on Mladina Classification:

The CT scans of both Group A and Group B were assessed and compared according to the Mladina classification. In Group A, we observed that 92.5% (n=37) had septal deviation, with Type III (35%) most common, while in Group B, 90% (n=30) patients had septal deviation, of which Type VI (35%) was most common. On comparing ACP and septal deviation between the groups using Fishers’s exact test, p value equals 0.098 indicating that there was no significant association between

deviation of nasal septum and polyp formation. (Table. 2)

Comparison based on location of most deviated point of nasal septum:

In the Group A, majority had Type III septal deviation (50%) i.e.; deviation in the nasal septal region between anterior and posterior edge of the middle turbinate while in control group, most had Type II septal deviation 65.0% (n=26).

Fisher’s exact test was p value = 0.001, indicating statistical significance (Table.2).

Comparison based on Baumann Classification:

According to Baumann classification, 32.5% (n=13) patients had Type III septal deviation in Group A while in control group, 27.5% (n=11) patients had Type V septal deviation. Fisher’s exact test demonstrated p value = 0.805 indicating no statistical significance (Table. 2).

Table 2. Comparison between groups based on Mladina Classification, Baumann Classification and most prominent point of deviated nasal septum

	Mladina classification		p value
Categories	Group A (cases)	Group B (controls)	
I	2(5%)	2(5%)	0.098
II	1(2.5%)	1(2.5%)	
III	14(35%)	6(15%)	
IV	7(17.5%)	4(10%)	
V	9(22.5%)	9(22.5%)	
VI	4(10%)	14(35%)	
No Deviation	3(7.5%)	4(10%)	
	Baumann classification		
I	4(10%)	4(10%)	0.805
II	3(7.5%)	6(15%)	
III	13(32.5%)	8(20%)	
IV	4(10%)	3(7.5%)	
V	8(20%)	11(27.5%)	
VI	5(12%)	4(10%)	
No Deviation	3(7.5%)	4(10%)	
	Most prominent point of deviated nasal septum		
I	4(10%)	9(22.5%)	0.001*
II	13(32.5%)	26(65%)	
III	20(50%)	1(2.5%)	
No Deviation	3(7.5%)	4(10%)	

*Statistical significance

Discussion

In this study, we aimed to investigate the relationship between an Antrochoanal polyp and deviated nasal septum. Ours is the only study to use three different classifications of septal deviation analyzed by two independent radiologists, to observe the correlation between DNS and the site of ACP formation. We observed that 92.5% (n=37) of patients with ACPs displayed some degree of deviation of nasal septum. Interestingly, the side of the polyp often corresponded to the same side as that of the deviation of the septum (37% right polyp with right deviation, 55% left polyp with left deviation). The relation of the side of Antrochoanal polyp and septal deviation was not significant in other studies (12,13).

To assess the degree and location of septal deviation within both groups, we utilised three distinct classification methods. Mladina classification was used, which categorises septal deviation based on its overall shape and location within the nasal cavity. In our study, the majority of the patients with ACPs had Type III septal deviation, 35% (n=14) compared to the control group, 15% (n=6). However, no statistical significance (p -value = 0.098) was noted, which suggests no association of the laterality of septal deviation

with ACP formation. Rozendorn et al (12) used the Mladina classification to observe any correlation of septal deviation and site of ACP based on CT scan findings. This study did not show any statistical significance between septal deviation and ACP. In the analysis of the data using classification based on the most deviated point of nasal septum, statistical significance (p value = 0.001) was noted, and Type III septal deviation was more common in Group A (50%), i.e. deviation between the anterior and posterior ends of the middle turbinate. Type III deviation can significantly obstruct the middle meatus, a crucial nasal passage. This obstruction might lead to negative pressure within the maxillary sinus, the cavity housing the ACPs (14). This negative pressure could theoretically create a suction effect, drawing existing intramural cysts within the sinus outwards and contributing to ACP formation. Possible mechanisms behind this connection are altered airflow dynamics, mucosal inflammation and osteomeatal complex dysfunction. The Baumann classification system which categorises septal deviations based on their angulation relative to the perpendicular plane of the skull base, was utilised (11). Interestingly, the Baumann classification did not yield statistically

significant results (p -value = 0.805). This suggests that the overall angulation might be less important than the specific location and shape of the deviation within the nasal cavity for ACP formation. Hekmatnia A et al. (13) in their case-control study observed a higher incidence of septal deviation in patients with ACP than the control group ($P < 0.001$). Aydin S et al, (6) in their case-control study comparing septal deviation and maxillary sinus volumes observed statistically significant maxillary sinus volumes on the AC polyp side in comparison to healthy controls. They observed that out of 76 patients, 53 had septal deviation, with 36 having the ACP polyp on the opposite side. Yan et al. (15) in their study included septal anatomic variations, volume of maxillary sinus, parameters related to the middle meatus, and compared with ACP formation. They did not observe any significance with nasal septal deviation ($p=0.450$). However, they observed statistically significant findings between the size of the accessory maxillary sinus ostium, maxillary sinus volume and dimensions in the osteomeatal complex region between the ACP and the non-ACP, which could have contributed to the formation of a polyp.

In the 3D model study of deviated nasal septum and normal cavity, on analysis of the airflow patterns, there was higher nasal resistance, higher by 38%–55% in the deviated nasal septum side. The nasal cavity with septal deviation had higher pressure drop values by 60%–120% more in the mid region than observed in the healthy nasal cavity region of the nasal valve (16). The changes in airflow patterns can affect the OMC area, hinder proper drainage and ventilation of the sinus and create a favourable environment for cyst development and subsequent ACP formation. Sinus inflammation due to septal deviation may contribute to predisposition to chronic rhinosinusitis (CRS) by three physiopathological ideas: changes in sinus ventilation and antral pressures due to septal deviation, mechanical causes due to obstruction of the osteomeatal complex, causing mucus stagnation. The third being the aerodynamic theory, which suggests that an alteration in the air pressure flow in the paranasal sinus and mucociliary clearance disruption leads to inflammation, potentially triggering the growth of cysts that eventually protrude as ACPs. The

osteomeatal complex (OMC) is a narrow passage connecting the maxillary sinus to the nasal cavity (17,18).

The exact cause or aetiology of ACP continues to be a subject of debate, with numerous theories vying for explanation. Some theories point towards allergic reactions or chronic inflammation as culprits, while others implicate cystic fibrosis or anatomical variations. One theory proposes a link between increased pressure within the nasal cavity due to anatomical features like a deviated septum and ACP formation. This theory suggests that the pressure might force an existing intramural cyst within the maxillary sinus to herniate outwards through an accessory opening, ultimately leading to the development of an ACP (2). This study delves into this very question, aiming to shed light on the potential role of septal deviation in ACP formation.

Based on our findings and conflicting views in the literature about the relationship between septal deviation and ACP, we would like to propose two possible theories. Firstly, that septal deviation leads to nasal obstruction, subsequent inflammation of the sinus lining and predisposes to rhinosinusitis and further ACP formation. Secondly, mechanical obstruction of the middle meatus causes changes in sinus ventilation, contributing to ACP formation.

The limitations of our study were the sample size, and we had not taken into consideration other anatomic parameters around the OMC, the maxillary sinus volume and accessory maxillary sinus ostia dimensions. Our study limits the ability to establish causality; however, the key finding being the statistically significant association between Type III septal deviation, characterised by a middle-third deviation, may be a contributory factor to the formation of ACP. Longitudinal studies tracking participants over time could provide a clearer picture of the role of septal deviation in ACP formation.

Conclusion

In the present study, we were unable to establish a definitive causality between deviated nasal septum and the occurrence of an Antrochoanal polyp. However, deviation of the nasal septum between the anterior and posterior ends of the middle turbinate may act as a contributory factor in the formation of ACP.

References

1. Killian G. The origin of choanal polypi. *Lancet* 1906;2:81-2
2. Frosini P, Picarella G, De Campora E. Antrochoanal polyp : analysis of 200 cases. *Acta Otorhinolaryngol Ital.* 2009 Feb;29(1):21-6. PMID: 19609378; PMCID: PMC2689564.
3. Ruysch F. *Observationum anatomico-chirurgicaram anturca.* 1691.
4. Zuckerkandl E. *Normale und pathologische Anatomie der Nasenholme.* Vienna 1892.
5. Brown K. Nasal antral polyposis. *Lancet* 1909; 1:89-91.
6. Aydın S, Taskin U, Orhan I, et al. The analysis of the maxillary sinus volumes and the nasal septal deviation in patients with ACPs. *Eur Arch Otorhinolaryngol.* 2015 Nov;272(11):3347-52. doi: 10.1007/s00405-014-3460-1. Epub 2014 Dec 23. PMID: 25534286.
7. Guven M, Karabay O, Akidil O, Yilmaz MS, Yildirim M. Detection of staphylococcal exotoxins in ACPs and chronic rhinosinusitis with nasal polyps. *Otolaryngol Head Neck Surg* 2013; 148(2): 302–307.
8. Berg O, Carenfelt C, Silfverswärd C, Sobin A. Origin of the choanal polyp. *Arch Otolaryngol Head Neck Surg* 1988; 114(11):1270–1271.
9. Nasal septal deformities in ear, nose, and throat patients: an international study. Mladina R, Cujic E, Subarić M, Vuković K. *Am J Otolaryngol.* 2008; 29:75–82. doi: 10.1016/j.amjoto.2007.02.002.
10. Serifoglu I, Oz İİ, Damar M, Buyukuysal MC, Tosun A, Tokgöz Ö. Relationship between the degree and direction of nasal septum deviation and nasal bone morphology. *Head Face Med.* 2017; 13(1): 3. Published 2017 Feb 28. doi: 10.1186/s13005-017-0136-2
11. Baumann I, Baumann H. A new classification of septal deviations. *Rhinology.* 2007 Sep;45(3):220-3. PMID: 17956023.
12. Rozendorn N, Warman M, Zloczower E, Mansour J, Yakirevitch A. Significance of nasal septal deviation among patients with antrochoanal polyp. *J Laryngol Otol.* 2023 Aug;137(8):921-924.
13. Hekmatnia A, Shirvani F, Mahmoodi F, Hashemi M. Association of anatomic variations with antrochoanal polyps in paranasal sinus computed tomography scan. *J Res Med Sci.* 2017;22:3. Published 2017 Jan 27. doi:10.4103/1735-1995.199085
14. Liu T, Han D, Wang J, Tan J, Zang H, Wang T, Li Y, Cui S. Effects of septal deviation on the airflow characteristics: using computational fluid dynamics models. *Acta Otolaryngol.* 2012 Mar; 132(3): 290-8. doi: 10.3109/00016489.2011. 637233. Epub 2011 Dec 27. PMID: 22201479.
15. Yan H, Bao X, Jiang T, Li T, Fu W, Guo M, et al. The anatomical variations of paranasal sinuses may be related to the formation of antrochoanal polyp by computed tomography imaging study. *Quant Imaging Med Surg* 2024;14(1):592-603
16. Corda JV, Shenoy BS, Lewis L, K. P, Khader SMA, Ahmad KA, et al. Nasal airflow patterns in a patient with septal deviation and comparison with a healthy nasal cavity using computational fluid dynamics. *Front. Mech. Eng.* 2022;8:1009640. doi: 10.3389/fmech.2022.1009640
17. Malpani SN, Deshmukh P. Deviated Nasal Septum a Risk Factor for the Occurrence of Chronic Rhinosinusitis. *Cureus.* 2022;14(10):e30261. Published 2022 Oct 13. doi:10.7759/cureus.30261
18. Iliadis AA, Goto H, Naclerio RM. Pathomechanisms of rhinosinusitis: a review. *Eur Arch Otorhinolaryngol.* 2009; 266(7), 1033-1041.