

## The value of chest x -ray in foreign body aspiration of children

\***Motaghi H. MD<sup>1</sup>, Jafarzadeh M. MD<sup>2</sup>, Poorahmadi S. MD<sup>3</sup>**

<sup>1,2,3</sup> Assistant professor of pediatrics- Mashhad University of Medical Sciences

### Abstract

**Introduction:** Foreign body aspiration (FBA) is a common cause of respiratory distress in children. Delay in diagnosis and treatment can cause serious complication especially chronic pneumonia. The aim of this study was evaluation of plain chest X- Ray (CXR) as the first and available imaging modality in FBA of children.

**Materials and Methods:** A retrospective analysis was conducted on the records of pediatric patients less than 18 years of age with the discharge diagnosis of FBA from 1999 to 2003 at the Imam Reza Hospital (a large tertiary center in Khorasan province).

**Results:** From 140 patients with FBA 87 (62%) were male. The mean age was 48 month. The most common clinical findings were: history of choking (77%), decreased breath sounds (42%), wheezing (38%), cough (20%), respiratory distress (15.5%) and fever. CXR was normal in 47% of patients with a sensitivity about 64%. Air trapping (Emphysema) was most common radiological findings (24.5%). Other radiological finding were, consolidations (10.5%), atelectasis (6.5%) and opaque foreign bodies (6.5%). In all cases except four cases, aspirated foreign bodies were food materials and watermelon seeds were the commonest one (40%). Bronchoscopic removal of foreign body was done successfully in 133 patients (95%).

**Conclusion:** Although FBA in children diagnosed by history, physical examination and radiographic findings, but this findings may be misleading. Negative CXR should not preclude diagnosis of FBA in children with a strong history of FBA, and early bronchoscopic examination will be safe and life saving.

**Key words:** Foreign body aspiration, Chest X-Ray, Children

### Introduction:

**F**oreign body aspiration (FBA) can be a life threatening emergency requiring immediate intervention. Foreign body aspiration typically occurs in children and manifests as obstructive lobar or segmental over inflation or atelectasis in CXR. Although radiographic studies are often obtained, decision for surgical intervention is usually based on a suspicious history and physical examination. The aim of this study was evaluation of plain CXR finding as the

first and available imaging modality in FBA of children.

### Materials and Methods

Form 1998 to 2003 the medical records of 140 children less than 18years old age with discharge diagnosis of FBA at Imam Reza Hospital a large tertiary referral center were reviewed. Patients with nasopharyngeal foreign bodies were excluded. Clinical and, radiological findings analyzed statistically.

Address: Department of pediatrics- Emam Reza Hospital  
Mashad . Tel: 0511-8543031(2248)

Email: H-motaghi@mums.ac.ir

Acceptation date: 84/3/29 Confirmation date: 84/5/30

## Results

From 140 patients 87 (62%) were male and 53 (38%) were female. The mean age was 48 months and the peak incidence of aspiration occurred during 1-6

years, accounting for 82.2% of the total cases. The signs and symptoms are outlined in (Table 1).

**Table 1-** Frequency of symptoms and signs in children with FBA

| Symptoms and Signs         | Silva AB (1)* | Baharloo (9) * | Present Study |
|----------------------------|---------------|----------------|---------------|
|                            | No (%)        | No (%)         | No (%)        |
| Chocking                   | 82(86)        | 48(49)         | 109(77)       |
| Wheezing                   | 76(81.7)      | 25(26)         | 54(38.6)      |
| Decreased breathing Sounds | 47(50)        | 25(26)         | 59(42)        |
| Cough                      | 39(42)        | 36(37)         | 98(20)        |
| Respiratory Distress       | 17(18)        | -----          | 7(15.4)       |
| Fever                      | 16(17)        | 30(31)         | 7(15.4)       |
| Pneumonia                  | 14(15)        | -----          | 6(4.6)        |
| Stridor                    | 7(7.5)        | -----          | 3(6.6)        |

\*Reference No

The most frequent symptom was sudden onset of choking as seen in 77% of patients. Radiographic findings are shown in (Table 2). Foreign body was food materials in all

except four cases which usually are nonopaque. Nearly half of the organic aspirated foreign bodies were watermelon seeds.

**Table 2-** Radiographic Findings in patients with FBA

|                      | Baharloo(9)* | Tokar (5)* | MU (11)* | Preesen study |
|----------------------|--------------|------------|----------|---------------|
|                      | No (%)       | No (%)     |          |               |
| Visible foreign body | 3(4)         | 30(30)     |          | 8(5.7)        |
| Air trapping         | 49(64)       | 68(82)     | 77(41)   | 34(24.5)      |
| Pneumonia            | 10(13)       | 34(69)     | 43(24)   | 13(10.5)      |
| Atelectasis          | 11(4)        | 37(67)     | 33(18)   | 9(6.4)        |
| Normal CXR           | 9(12)        | 51(68)     | 29(14)   | 66(47.1)      |

The main sites of foreign body was right bronchus in (38.6%), left bronchus in (22%) and carina in (23.6%). Frothy two percent of the patients presented immediately, that is within 24 hours after aspiration. In 133 patients (95%), the foreign body removed successfully under general anesthesia using rigid bronchoscope. Complication was seen in 5.7% of patients, include cardiac arrest (1), laryngospasm (5), pneumothorax (1) and pneumomediastinum (1). The mean of hospital stay was 2 days and mortality rate was 2.9 %.

## Discussion

Most tracheobronchial foreign bodies in children are food materials which are radiolucent, so accurate diagnosis of such foreign bodies is not always easy. Children may present without any history of aspiration or an atypical history with nonspecific symptoms.

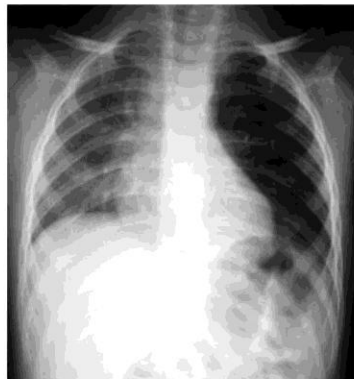
Accurate history and a high index of suspicion are needed to prevent delayed diagnosis and the complications (1-4).

The most common signs and symptoms of foreign body aspiration are choking, coughing, wheezing and decreased breathing sounds. (5,6). The history of choking crisis showed sensitivity and specific of 97% and 93% respectively Other findings such as radiography has a high sensitivity (85%) but low specificity (9%).

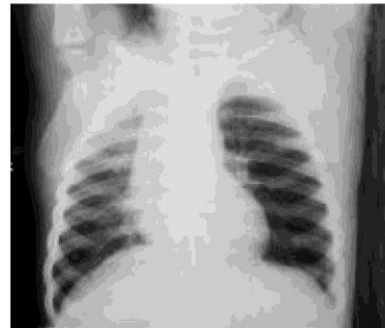
We found that of all signs and symptoms, the most predictive one is choking history and radiologic findings with a sensitivity of 81% and 64% respectively.

Radio-opacity of aspirated foreign bodies prevent misinterpretation of the symptoms and provides an early and accurate diagnosis. As we determined in our study, most aspirated foreign bodies were radiolucent, and only 5.7% of foreign bodies were opaque.

In children younger than 3 years, 80% of airway foreign bodies was food materials or other radiolucent items (8,9). Unilateral obstructive emphysema is the typical indirect radiological sign of radiolucent objects (1,6,9, 10, 12). In our study the most significant indirect radiological finding was emphysema (24.5%) (figure 1, 2).

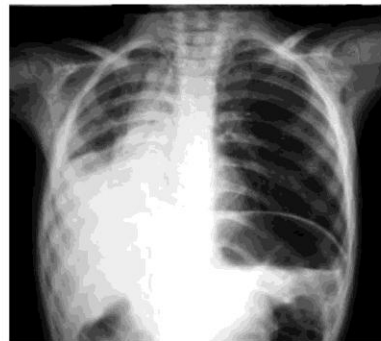

**Fig 1:** A chest radiograph of a 5 years old girl with persisting cough demonstrates left lung air trapping.



**Fig 2:** Left lateral decubitus chest radiograph demonstrates failure of mediastinal shift. A watermelon seed was found in left main stem bronchus during bronchoscopy

While emphysema and hyperlucent lung observed in early stage of foreign bodies, atelectasis or consolidation indicates fairly advanced stage (13) (figure 3).



**Fig 3:** A 4 years old boy presenting by abdominal Pain and respiratory distress. Atelectasis of the lower right lung is noted. A watermelon seed was found in the right mainstem bronchus during bronchoscopy.

Plain chest radiography showed atelectasis in 18% of patients with foreign body aspiration (11). In present study atelectasis was determined in 6.5% of the patients. Atelectasis is more common in the adults (9).

From seventy four of the cases with non opaque foreign bodies, twenty three patients had normal radiographs .(14) The proportion of normal radiographs reported in the literature varies form 8% to more than 80% , depending on the study and location of foreign body (9).

In present study 66 patients (47%) had normal radiographs. So if the clinician only rust the radiological finding and does not consider an early bronchoscopy in patients with strong history, the diagnosis can be delayed. This is important, because the longer a foreign body is left in situ, the grater the inflammation and the likelihood of complications. If an expiratory film can not be obtained due to lack of cooperation or negative radiological finding, the fluoroscopy may be helpful. Although CT Scan occasionally demonstrates an opacity not visualized on the plain film, it should not be considered as one of the initial diagnostic methods for foreign body aspiration (10). Computerized tomography (CT) scanning has been help full in child whom all other modalities, including surgical exploration, had failed to localized a foreign body. Combining our experience with that in literature, convincing history and plain chest radiography are two main criteria for the diagnosis of FBA Rigid bronchoscopy under general anesthesia was preferred method for removal of aspirated foreign body. Complications of bronchoscopy for foreign body aspiration are uncommon but occur even in experienced hands. In one study bronchoscopy was succeeded in 558(99%) of children life threatening complication occurred in 21 (4%) and death in 5 patient (0.8%).

In present study bronchoscopic removal of foreign bodies was succeeded in 133 (95%) patients and the life threatening complication occurred in 8 (5.7%) patients. There were 2 (9%) deaths.

### Conclusion

Children with foreign body aspiration

may present with atypical misleading history, clinical and radiological findings. History and plain chest radiography are two main criteria for the diagnosis of FBA Regardless of radiological findings, when foreign body aspiration is suspected in a patient with a history of choking, a transient cyanosis and coughing, early bronchoscopic examination should be considered. Negative radiography and fluoroscopy should not preclude bronchoscopy in patients with a strongly history of foreign body aspiration.

### Acknowledgements

The authors wish to thank Ms. Sadjadi (Radiologist) and Spastics and Research centre of Emam-Reza hospital for kind collaboration.

### References

- 1- Silva AB, Muntz HR, Clary R. Utility of conventional radiography in the diagnosis and management of pediatric airway foreign bodies. *Ann otol Rhinol Laryngol*1998.; 107 (10): 834-8.
- 2- Reilly J, Thompson J, Mae A et al. Pediatric aerodigestive foreign body injuries are complications related to timeliness of diagnosis. *Laryngoscope*1997; 107(1):17-20.
- 3- Ciftci AO, Kologlum BM et al. Bronchoscopy for evaluation of foreign body aspiration in children. *J Pediatr Surg* 2003; 38(8): 1170-6.
- 4- Walner DL et al .Utility of radiographs in the evaluation of pediatric upper airway obstruction. *Ann Oto Rhinol Laryngol*1999; 108(4):378-83.
- 5- Tokar B, Ozkan R. Ilhan H. Tracheobronchial foreign bodies in children: importance of accurate history and plain chest radiography in delayed presentation. *Clin Radiol* 2004. 59 (7): 609-15.
- 6- Zerellay T et al. Foreign body aspiration in children. Value of radiography and complications of bronchoscopy. *J Pediatr Surg*1998; 33 (11): 1651-4.
- 7- Fontoba B et al .Bronchial foreign body:

should bronchoscopy be performed in patients with choking crisis? *Pediatr surg Int* 1997; 12(2-3): 118-20.

8- Deskin R, Young G, Hoffman R. Management of pediatric aspirated foreign bodies. *Laryngoscope* 1997; 107: 540-548.

9- Baharloo F et al. Tracheobronchoial foreign bodies. Presentation and management in children and adults. *Chest* 1999; 115 (5): 1357-62.

10- Wunsch R, Wansch C, Darge K. Foreign body aspiration. *Radiology* 1999; 39 (6): 467-71.

11- Mu L, He P, Sun D. The causes and complications of late diagnosis of foreign

body aspiration in children. *Arch otolaryngol Head Neck Surg* 1991; 117(8); 876-9.

12- Emir H et al. Bronchoscopic removal of tracheobronchial foreign bodies. *Pediatr surg Int* 2001; 17(2-3): 85-7.

13- Tomiyama N et al. Chest radiograph of foreign bodies in the tracheobronchial. *Nippon Igaku Hoshasen Gakkai Zasshi* 1991; 5(8): 923-8.

14- Reed MH. Radiology of airway foreign bodies in children. *J can Assoc Radiol* 1977; 28 (2):111-8.

\*\*\*\*\*

#### خلاصه

### رادیوگرافی ساده قفسه صدری در آسپیراسیون جسم خارجی کودکان

دکتر حسن متقی مقدم، دکتر محسن جعفرزاده، دکتر صادق پوراحمدی

**مقدمه:** آسپیراسیون جسم خارجی یک علت شایع دیسترس تنفسی در کودکان است تاخیر در تشخیص و درمان آن می تواند منجر به عوارض جدی به ویژه پنومونی مزمن شود. هدف این مطالعه ارزیابی نقش رادیوگرافی ساده قفسه صدری در تشخیص آسپیراسیون جسم خارجی به عنوان یک اقدام اولیه و در دسترس است.

**روش کار:** این مطالعه به صورت گذشته نگر طی سال های ۸۳-۱۳۷۹ در بیمارستان امام رضا (ع) وابسته به دانشگاه علوم پزشکی مشهد انجام گردید. اطلاعات موجود از پرونده بیماران کمتر از ۱۸ سال که با تشخیص آسپیراسیون جسم خارجی ترخیص شده بودند، استخراج و یافته های حاصله با مطالعات مشابه مقایسه و تجزیه و تحلیل آماری گردید.

**نتایج:** از مجموع ۱۴۰ بیمار ۸۷ نفر آن (۶۲٪) مذکر بودند. متوسط سن بیماران ۴۸ ماه بود. شایع ترین یافته های بالینی عبارت بودند از: شرح حال Chocking (۷۷٪)، کاهش صداهای تنفسی (۴۲٪)، خس خس سینه (۳۸٪)، سرفه (۲۰٪)، دیسترس تنفسی (۱۵/۵٪) و تب. رادیوگرافی قفسه صدری در ۴۷٪ موارد طبیعی و حساسیت تشخیصی ۶۴٪ بود. پرهوائی شایع ترین یافته های رادیوگرافیک بود (۲۴/۵٪). سایر یافته های رادیوگرافیک به ترتیب شیوع عبارت بودند از: کدورت روی (۱۰/۵٪)، اتلکتازی در (۶/۵٪)، اپاسیته ناشی از جسم خارجی در ۶/۵٪. به جز چهار مورد جسم خارجی آسپیره شده مواد خوراکی بود که تخم هندوانه شایع ترین آنها بود (۴۰٪). در ۱۳۳ بیمار (۹۵٪) جسم خارجی به طور کامل و موفقیت آمیزی با برونکوسکوپی خارج شده بود.

**نتیجه گیری:** اگر چه تشخیص جسم خارجی کودکان با شرح حال، معاینه فیزیکی و یافته های رادیولوژیک محقق می گردد. لیکن این یافته ها ممکن است گمراه کننده نیز باشند. رادیوگرافی قفسه صدری طبیعی به ویژه در مواردی که شرح حال قویاً به نفع تشخیص است نباید موجب کنار گذاشتن تشخیص آسپیراسیون جسم خارجی گردد و برونکوسکوپی روشی بی خطر و نجات بخش است.

**واژه های کلیدی:** آسپیراسیون جسم خارجی، رادیوگرافی قفسه صدری، کودکان