

Large giant cell tumor of the temporal bone presenting as mild conductive hearing loss

Khadivi E. MD¹, Poorsadegh M. MD², Bakhshae M. MD³,
khooei A. MD⁴, zamanian A. MD⁵

^{1,3}Assistant professor of otorhinolaryngology, ²Associated professor of otorhinolaryngology,
⁴Associated professor of anatomical pathology, ⁵Assistant of otorhinolaryngology-
Mashhad University of Medical Sciences

Abstract

Introduction: Giant cell tumor of bone or osteoclastoma is a relatively rare primary neoplasm of temporal bone. It usually involves the epiphyseal region of long bones. Primary involvement of bones of the skull appears to be uncommon.

Case report: we report a case of giant cell tumor of temporal bone arising in a 33 years old man. The presenting symptom is only mild conductive hearing loss. A computed tomography (CT) scan showed a large well circumscribed mass within the right temporal bone, the posterior cranial fossa and the infratemporal fossa. Biopsy and subsequent resection showed a giant cell tumor of bone.

Conclusion: Temporal bone tumor may be presented with symptoms such as mild hearing loss or aural fullness. So we always must be attention rare reasons of common symptoms.

Key words: Hearing loss, Giant cell tumors, Temporal bone

Introduction

Giant cell tumor of bone or osteoclastoma is a relatively rare primary neoplasm. Constituting approximately five percent of all primary bone tumors. The tumor is given its name due to the presence of numerous osteoclast-like giant cells (1). Giant cell tumors usually involve the epiphyseal region of long bones and primary involvement of the bones of the skull appears to be uncommon and preferentially involves the sphenoid and temporal bones of the middle cranial fossa. These bones arise, as do long bones, through a process of endochondral bone formation (2).

*Address: ENT department, Imam Reza Hospital Mashhad
Email: chn-khadivi@mums.ac.ir
Acceptation date: 84/12/14 Confirmation date: 85/4/26

Case report

A 33 years old man presented initially to the ENT clinic at the Imam Reza Hospital, with a four-month history of mild hearing loss and fullness in the right ear. Initial examination showed sagging of the posterior external auditory canal wall. Cranial nerve examination revealed no abnormality.

Audiometric assessment demonstrated a conductive hearing loss of 25dB in the right ear with normal thresholds in the left ear. A computed tomography demonstrated a large, well-circumscribed mass arising within the right temporal bone (Figure 1).

And extending posteriorly to posterior cranial fossa.

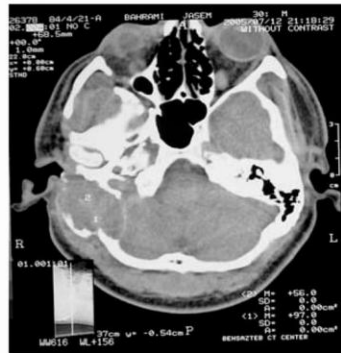

Fig 1: Axial tumor CT scanning.

The radiologic impression was of an aggressive neoplasm arising primarily with in the right temporal bone. Hematological and biochemical blood indices, including bone profile, were normal. There was no clinical or biochemical evidence of hyperparathyroidism. Chest X-ray showed no abnormality. Open biopsy was preformed and following the histological report, definitive surgery was performed. Tumor destroyed the posterior wall of the external ear canal and entered to the canal although tympanic membrane and ossicles were saved.

Tumor was developed to the posterior dura although dura wasn't destroyed. Tumor was curettages from the posterior to anterior in the appearance of anthroma. The posterior wall of the external ear canal was destroyed. Tumor was resected with preservation of tympanic membrane (Figure 2).

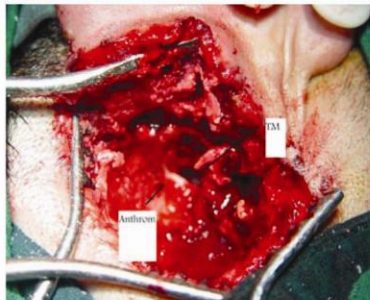


Fig 2: Normal TM and anthrom

The nerve canal was opened and nerve was free from the canal and followed to stylomastoid foramen. Tumor was completely dissected from the nerve and followed by interposition of palva flap in the cavity, which was formed after resection of tumor and a large meatoplasty was done. Facial nerve had mild paresis but after two weeks was turned to normal action. From histologic point of view, tumor was contained of mononuclear stroma cells like fibroblasts with penetration of the giant cells (Figure 4).

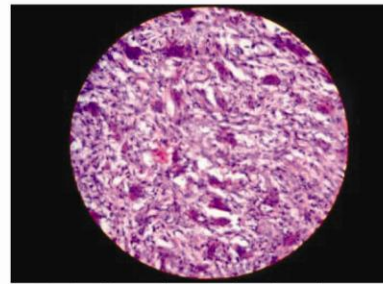


Fig 3: Photomicrography of specimen, H&E 10×10.

Discussion

Giant cell tumors affecting the temporal bone are rare. In a review of the literature, Zelig et al identified only 15 similar cases and 5 new cases have been reported since that time (3). The clinical features of giant cell tumor depend on their location. Conductive hearing loss occurred more in cases present in the mastoid, middle ear, or external auditory canal, whereas sensorineural hearing loss was reported in cases involving the petrous pyramid. MC Cluggage and MC Bride reported a case of giant cell tumor arising with in the temporal bone.

The patient had an unusual presentation. His chief complaint was of rotational vertigo and he initially presented to a vertigo clinic (1). The presence of pain or a mass was the next most common symptom. Wolf et al reported 10 cases of giant cell tumor of the sphenoid bone.

The presenting symptoms were varied and included headache, visual field defects, blindness and diplopia (4). Several single case reports of giant cell tumor of the temporal bone have also appeared in the literature that presented with a combination of symptoms, mainly pain, deafness and facial weakness (2, 5, 6).

The hearing loss often conductive, as in the present case, is most likely a result of the propensity of these tumors to obstruct the external ear canal. The patient in the present case had a post-operative facial weakness but after two weeks returned to normal action. Several of the previously reported cases of giant cell tumor of the temporal bone have demonstrated facial nerve weakness at presentation (5, 6).

Radiologically, these lesions don't have a distinguishing appearance and may simulate other expanding, destructive lesions of the temporal bone. Radiologic differential diagnosis includes chondrosarcoma, osteoblastomas, osteolytic metastasis, and other fibrous lesions (7). Histologically, these tumors consist of mononuclear ovoid and spindle-shaped stromal cells and multinucleated giant cells. Stromal cells are more significant because their behavior gives the lesion its character. Early reports failed to differentiate between giant cell tumors and giant cell reparative granulomas or other similar lesions. Both giant cell tumor and giant cell granuloma consist of osteoclast-like giant cells scattered in a background of stromal cells (8). Several authors have pointed out that giant cell tumor can histologically simulate giant cell granuloma. It has further been proposed that the two entities are essentially variants of the same disease process modified by the age of the patient and the site of occurrence. Be that as it may, frequently described histological differences between giant cell tumor and giant cell granuloma are:

- 1) The larger more rounded giant cell with a greater number of nuclei in the giant tumor.
- 2) The more common occurrence of fresh hemorrhage and hemosiderin deposits in the giant cell granuloma.
- 3) The more uniform dispersal of giant cells in the giant cell tumor.
- 4) The more frequent production of osteoid or new bone in the giant cell granuloma (1).

However, those purported differences have been questioned and many believe there is considerable overlap between the two lesions (3). One feature in the present case points to a diagnosis of giant cell tumor: the relatively even distribution of giant cells throughout the entire lesion. This is in contrast to giant cell granuloma where the giant cell tends to be unevenly dispersed and aggregated around areas of hemorrhage. In addition, the radiological appearance in the present case was suggestive of an aggressive tumor.

The radiological appearance of giant cell granuloma is of a lytic area, which only rarely expands the bone (7). All giant cell tumors should be regarded as potentially malignant in view of the fact that as many as 30 to 50 percent recur after curettage and five to 10 percent give rise to distant metastases. The most common site of metastasis by far, is the lungs (1). The currently preferred treatment is through curettage with bone grafting, or en bloc excision with replacement with allograft or artificial material, depending on the location of the tumor. Special care should be taken to prevent implantation of tumor. Special care should be taken to prevent implantation of tumor into the adjoining soft tissue (9, 10). McDonald in a large series with giant cell tumor of bone reports, the recurrence rate was 34 percent following curettage and seven percent following wide resection (11). The value of post-operative radiation therapy in management of these tumors is controversial.

Some believe that radiation therapy should be reserved only for cases in which complete surgical removal is impossible (9, 12). Others believe that because of the seeming inevitability of recurrence with an incomplete resection and because of the apparent safety and effectiveness of modern radiotherapeutic techniques, optimal therapy in the cases of a tumor involving the bones of the skull consists of radical resection followed by carefully planned and delivered irradiation (5).

Reference

- 1- Cluggage WG, Bride CB, Primrose WJ. Giant cell tumor of the temporal bone presenting as vertigo. *J Laryngol Otol* 1995; 109(6): 538-41.
- 2- Pradhan S, Datta NR, Krishnani N, Ayyagari S, Tandon P. Giant cell tumor of the petrous bone. *Indian Journal of Cancer* 1991; 28: 177- 180.
- 3- Saleh EA, Taibah AK, Naguib M, Aristegui M. Giant cell tumor of the lateral skull base: 2 case report. *Otolaryngol Head Neck Surg* 1994; 111(3P+1): 314-18.
- 4- Wolfe JT, Scheithauer BW, Dahlin DC. Giant cell tumor of the sphenoid bone: review of ten cases. *Journal of Neurosurgery* 1983; 59: 322-327.
- 5- Findlay JM, Chiasson D, Hudson AR, Chui M. Giant cell tumor of the middle cranial fossa. *Journal of Neurosurgery* 1987; 66: 924 - 928.
- 6- Epstein N, Whelan M, Reed D. Giant cell tumor of the skull: a report of two cases. *Neurosurgery* 1982; 11: 263 - 267.
- 7- Silvers AR, Som PM, Brand WM. The role of imaging in the diagnosis of giant cell tumor of the skull base. *Neuroradiol* 1996; 17: 1392 - 95.
- 8- Auclair PL, Cuenin P, Kratochvil FJ, Slater LJ. A clinical and histomorphologic comparison of the central giant cell granuloma and the giant cell tumor. *Oral Surgery, Oral Medicine, Oral Pathology* 1988; 66: 197 - 208.
- 9- Donald DJ, Sim FH, Lead RA, Dahlin DC. Giant cell tumor of bone. *Journal of Bone and Joint Surgery* 1986; 68: 235-242.
- 10- Colclasure JB, Shea CM, Graham SS. Giant cell lesions of the temporal bone. *Am J Otol* 1981; 2: 188-92.
- 11- Jamieson KG. Osteoclastoma of the petrous temporal bone. *British Journal of Surgery* 1969; 56: 239-241.
- 12- Kinney SE, Sebek BA. Rare tumors of the skull base and temporal bone. *Am J Otol* 1985; 6: 135- 42.

خلاصه

**تظاهر اولیه تومور سلول ژانت استخوان تمپورال
به صورت کاهش شنوایی خفیف هدایتی**

دکتر احسان خدیوی، دکتر مهدی پور صادق، دکتر مهدی بخشایی، دکتر احمد خوبی، دکتر احمد زمانیان

مقدمه: تومور سلول ژانت استخوان گیجگاهی یا استئوکلاستوما یک نئوپلاسم اولیه نسبتاً نادر استخوان گیجگاهی است. او معمولاً ناحیه اپی فیز استخوان های بلند را گرفتار می کند درگیری اولیه استخوان های مجامه ناشایع است.

معرفی بیمار: ما یک مورد تومور سلول ژانت استخوان گیجگاهی در یک مرد ۳۳ ساله را گزارش می کنیم که تظاهر اولیه آن یک کاهش شنوایی هدایتی خفیف است. سی تی اسکن یک توده بزرگ با حاشیه مشخص در داخل استخوان گیجگاهی، حفره مجامه ای خلفی و حفره زیر گیجگاهی را نشان داد. بیوپسی و حذف توده متعاقب آن تومور سلول ژانت استخوان گیجگاهی را نشان داد.

نتیجه گیری: تومورهای استخوان گیجگاهی ممکن است با علائمی مثل کاهش شنوایی هدایتی خفیف یا پری گوش تظاهر کنند. بنابراین باید همیشه علل نادر علائم شایع را مد نظر داشته باشیم.

واژه های کلیدی: کاهش شنوایی هدایتی، تومور سلول ژانت، استخوان گیجگاهی