

## Tracheobronchopathia Osteochondroplastica (Case report)

\*Towhidi M. MD<sup>1</sup>, Katebi M. MD<sup>2</sup>, Attaran D. MD<sup>3</sup>, Omidi A. MD<sup>4</sup>

<sup>1</sup>Associated Professor of Internal Medicine, <sup>2</sup>Assistant Professor of Pathology,

<sup>3</sup>Assistant Professor of Internal Medicine, <sup>4</sup> Professor of Pathology-  
Mashhad University of Medical Sciences

### Abstract

**Introduction:** Tracheobronchopathia Osteochondroplastica (TO) or Tracheopathia Osteoplastica is a rare disorder of large airways with unknown etiology. The diagnosis is usually made on bronchoscopy and confirmed on histology. Generally it is benign and asymptomatic but it may lead to serious complication like airway obstruction requiring surgical treatment.

**Case reports:** We describe two cases of TO with characteristic bronchoscopic and histological findings. The first one had squamous cell carcinoma of the lung, and the second one had chronic rheumatoid arthritis associated with interstitial fibrosis.

**Keywords:** Tracheobronchopathia Osteochondroplastica, Tracheopathia Osteoplastica, Bronchoscopy, Airway obstruction

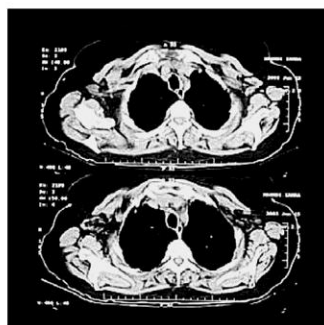
### Introduction

**T**racheobronchopathia Osteochondroplastica (TO) is a rare abnormality of the tracheobroncheal wall, characterized by the presence of osteocartilaginous calcified nodules within the submucosa, with some degree of tracheobronchial narrowing. Findings in CT scan are characterized by the presence of an abnormal irregularity and nodular densities protruding into the large airway lumen and histological evaluations confirming the diagnosis.

### Case report-No.1

A 47 year-old woman referred with the chief complaint of cough and progressive dyspnea with blood streaked sputum for one month. She was non-smoker with no weight loss and no fever. She had had occasional cough and exertional dyspnea for many years.

There was history of tuberculosis in her father. On physical examination there was no significant abnormality. Chest roentgenogram showed round opacity in left upper zone and CT scan revealed, characteristic nodules and calcifications on entire trachea and main bronchi (figure 1).

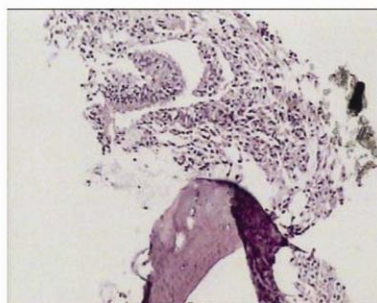


**Fig 1:** Nodules and irregular calcifications are seen on CT scan

\*Address: Department of pulmonary medicine-Ghaem Hospital- Mashhad University of Medical Sciences  
Tel: +9151145949 Email: dr\_mtowhidi@yahoo.com  
Acceptation date: 83/11/5 Confirmation date: 84/1/24

Fiberoptic bronchoscopy showed mucosal nodularity of trachea and main bronchi. Left upper lobe bronchus was stenotic. The endobronchial biopsy showed non specific inflammation and cytology was negative for malignant cell. Bronchial lavage was negative for acidfast bacilli.

Biopsy from tracheal nodules showed characteristic submucosal ossified nodule of TO (figure.2). Thoracotomy and lung biopsy showed squamous cell carcinoma (SCC).



**Fig 2:** Biopsy from tracheal nodules shows ossification in submucosa , characteristic of TO (H&E stain×400)

### Case report-No.2

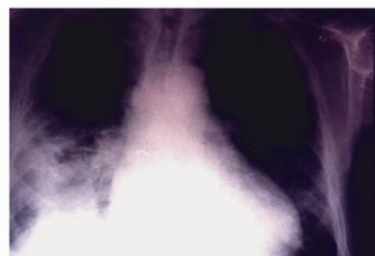A 58 year-old woman referred with the chief complaint of cough and dyspnea of 2 years duration. She has been smoking (water pipe) for 20 years.

Cough has been associated with frothy sputum. She lost weight recently, but had no fever. She gave history of arthralgia and joint swelling since many years ago which resulted in joint deformity especially in proximal interphalangeal (PIP) and metacarpophalangeal (MCP) joints of the hands. With a diagnosis of rheumatoid arthritis she received nonsteroid anti inflammatory drugs (NSAID) and prednisolone.

On physical examination she was emaciated without respiratory distress. She had flexion deformity of PIP joints of hands without swelling and arthritis.

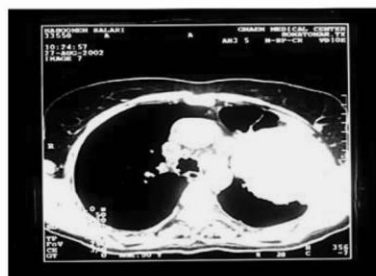There was decreased range of motion of wrists and elbows. Also there were few crackles in both posterior lung lower zones. Rheumatoid arthritis (RA) factor was positive. Sedimentation rate was 50 mm.

Chest roentgenogram showed bilateral interstitial and reticulonodular pattern in lower zones with honeycomb like appearance (figure 3).



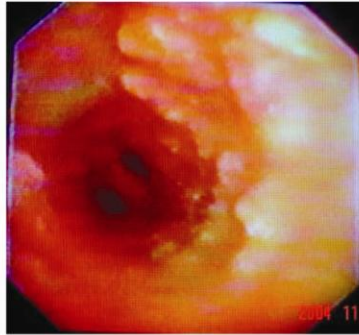**Fig 3:** Posteroanterior Chest x-ray reveals bilateral interstitial and reticulonodular pattern in lower zones with no clear evidence diagnostic of TO

CT scan revealed characteristic features of TO (figure 4).



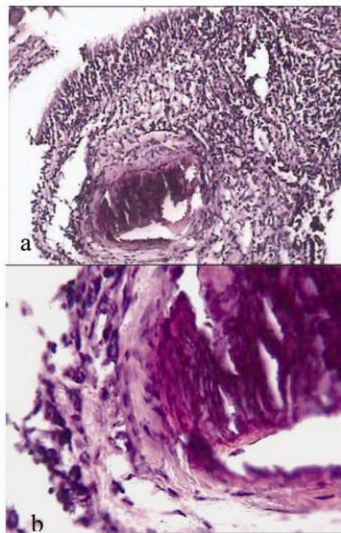
**Fig 4:** Nodules and irregular shell-like calcifications better seen on CT scan

Fiberoptic bronchoscopy showed mucosal nodularity from subglottic area extended to entire trachea and main bronchi, characteristic of TO with slight inflammation of right middle lobe bronchus (figure 5).



**Fig 5:** Fiberoptic bronchoscopy shows characteristic mucosal nodularity of TO

Biopsy of trachea showed submucosal ossifying nodule suggestive of TO (figure 6). Bronchial lavage for cytology and acid-fast bacilli were negative.



**Fig 6:** Biopsy of trachea shows submucosal ossified nodule characteristic of TO. H&E stain a -x100 (b-x400)

## Discussion

TO is one of the rare tracheobronchial diseases characterized by the presence of multiple submucosal osseous or cartilaginous or osteocartilagenous nodules protruded in tracheal and/or bronchial lumens(1,2).

It is more common in men over age 50 but also has been reported in young females (3). Disorder was first described by Walks in 1857 in a 38 year old man who died of tuberculosis (3, 4).

The true incidence of TO is not well known. In a prospective endoscopic study of 2, 180 patients over 8 year period, it was recognized in only 9 cases (3, 4) and in another study 4 cases were seen from 20,000 bronchoscopic examination (5).

Clinical presentation is variable, from asymptomatic in mild cases diagnosed at autopsy to extensive involvement and may produce symptoms of cough, exertional dyspnea, wheezing and hemoptysis (due to mucosal ulceration) (1- 3, 6).

Evaluation of patients by using spirometry shows obstructive pattern (6) and by imaging study, characteristic nodules or irregular shell like calcifications, better seen on CT scans and often not on conventional posteroanterior chest roentgenogram, but it may be more evident in lateral view (1,2,7).

On fiberoptic bronchoscopy hard masses of luminal protrusions of submucosal nodules can be seen and taken by forceps biopsy. Rarely during endoscopy, the larynx may be the only site of disease (1, 8). The lesions are most frequent in distal two thirds of trachea and major bronchi (1, 3, 9).

Histologically, nodules of hyaline cartilage and lamellar bone sometimes with active marrow are seen in submucosa between the normal cartilage and the surface of epithelium of airway and there may be connections between lesions or perichondrium of tracheal rings from collagenous or cartilaginous and /or osseous tissue (1).

Relevant to both the diagnosis and etiology of the condition is the observation that the membranous portion of the trachea is spared (12).

Etiology of this disorder is unknown and controversial (1) but may be due to degenerative exostosis or enchondrosis of the tracheal rings. Also correlation of disease with amyloidosis was described by Sakulla in 1968 as a late complication (1, 3,10,11).

In addition linking of TO with infection of *Mycobacterium Avium Intracellularis* has been postulated by Bagnee in 1995 (2, 13).

There have been few cases in association with lung cancer which seem to be more coincidental (3,9,14), Management of patients generally is conservative but using a rigid bronchoscope and dilatation and removal of some osseous lesions can be done. Other methods include: cryotherapy, laser therapy (6) and external beam radiotherapy (2). In general surgical management is indicated only when conservative treatments like antibiotics for infection etc. has failed (2, 3).

#### References

- 1- Pilch BZ. Larynx and trachea. In: Fletcher CDM. Diagnostic histopathology of tumors. 2ndEd. London: Churchill Livingstone;2000. p. 146.
- 2- Hopkinsone DN, Keshavjee S. Benign conditions/inflammatory conditions. In: Griffith PF, Cooper JD, Deslauriers J, Ginsberg RJ, Hiebert A, Patterson GA, Urschel HC. Thoracic surgery. 2<sup>nd</sup> ed. New York: Churchill Livingstone; 2002. p. 326-327.
- 3- Barthwal MS, Chatterji RS, Mehta A. Tracheobronchopathia Osteochondr oplastica. Indian J Chest Dis Allied Sci 2004;46:43-43.
- 4- Fraser RS, Colman N, Muller NL, Pare PD. Diagnosis of Diseases of the Chest. 4th ed. Philadelphia: W.B. Saunders Company; 1999. p. 2042.
- 5- Nierop MA, Wagenaar SS, Bosch JMM, Westermann CJ. Tracheobronchopathia Osteochondroplastica. Eur J Respir Dis 1983; 64: 129-33.
- 6- Prakash UB, Cullough AE, Edell ES, Nienhuis DM. Tracheopathia osteoplastica: Familial occurrence. Mayo Clin Proc 1989; 64: 1091-96.
- 7- Restrepo S, Pandit M, Villamil MA, Rojas IC, Perez JM et al. Tracheobronchopathia osteochondroplastica: helical CT findings in 4 cases. J Thorac Imaging 2004; 19 (2):112-6.
- 8- Paaske PB, Tang E. Tracheopathia osteoplastica in the larynx. J Laryngol Otol; 1985; 99 (5): 305-10.
- 9- Meyer CN, Dossing M, Broholm H. Tracheobronchopathia osteochondroplastica. Respir Med 1997; 91(8): 499-502.
- 10- Mathlouthi A, Rehouma C, M' Rad S et al. Tracheobronchopathia osteochondroplastica: Personal observation and review of literature. Rev Pneumol Clin 1993; 49(3): 156-62.
- 11- Toyoda M, Ebihara Y, Kato H, Kita S. Tracheobronchial AL amyloidosis: histologic, immunohistochemical, ultra structural, and immunoelectron microscopic observations. Hum Pathol 1993; 24 (9):970-6.
- 12- Corim B. Metabolic diseases In: Corrin B. The lungs. Third ed. London: Churchill Livingstone; 1990. p. 263-279.
- 13- Baugnee PE, Delaunois LM. Mycobacterium avium-intracellulare associated with tracheobronchopathia osteochondroplastica. Eur Respir J 1995; 8 (1):180-2.
- 14- Roggenbuck C, Hau T, Wall N, Buss H. Simultaneous occurrence of tracheobronchopathia osteochondropastica and mucoepidermoid carcinoma. Chirurg 1995; 66 (3):231-4.

\*\*\*\*\*

## خلاصه

**تراکتو برونکوپاتیا استئوپلاستیکا، گزارش دو مورد**

دکتر محمد توحیدی، دکتر مهرداد کاتبی، دکتر داوود عطاران، دکتر عباسعلی امیدی

**مقدمه:** تراکتو برونکوپاتیا استئوپلاستیکا یا تراکتوپاتیا استئوپلاستیکا یک اختلال نادر مجاری هوایی بزرگ با علت ناشناخته است. معمولاً تشخیص بر اساس مشاهدات برونکوسکوپی است که با نتایج مطالعه بافتی تایید می شود. این ضایعات عموماً خوش خیم و بدون علامت است اما ممکن است منجر به عوارض بسیار شدید مانند انسداد راه هوایی شده و نیازمند مداخلات جراحی شود.

**گزارش مورد:** در این مقاله ما دو بیمار تراکتو برونکوپاتیا استئوپلاستیکا، با یافته های مشخص برونکوسکوپیک و بافتی این اختلال را شرح می دهیم. نمونه اول کارسینوم سلول سنگفرشی ریوی داشت و دومین بیمار همزمان دچار آرتریت روماتوئید و فیروز انترسیس بود.

**واژه های کلیدی:** تراکتو برونکوپاتیا استئوپلاستیکا، تراکتوپاتیا استئوپلاستیکا، برونکوسکوپی، انسداد راه هوایی