



## Mucormycosis of the lung, a rare cause for lung cavitations. case report

Mirsadraee M.MD<sup>1</sup>, Towhidi M.MD<sup>2</sup>, Attaran D.MD<sup>3</sup>, Sharifi N.MD<sup>4</sup>,  
Ghiasi Moghadam T.MD<sup>5</sup>, Sadrizadeh A.MD<sup>6</sup>

<sup>1</sup>Assistant Professor of Internal Medicine, Medical School of Islamic Azad University of Mashad, <sup>2</sup>Associated Professor of Internal Medicine, <sup>3</sup>Assistant Professor of Internal Medicine, <sup>4,5</sup>Assistant Professor of Pathology, <sup>6</sup>Associated Professor of Thoracic Surgery Mashad University of Medical Sciences

### Abstract

**Introduction:** Cavitory lung lesion is caused by serious lung pathology. Among rare causes is mucormycosis that should not be overlooked. High index of suspicion is necessary to avoid missed diagnosis especially in diabetic and immunosuppressed patients.

**Report of cases:** We present two cases with lung mucormycosis diagnosis. Case 1: A 58 year old male with history of diabetes, presented with hemoptysis. Chest X ray (CXR) showed cavitation. Bronchial lavage revealed mucor hypha that was proved again with lobectomy. Case 2: A 39 year old female with history of chronic renal failure and lung cavitory lesion due to previous necrotizing pneumonia. She suffered from cough, dyspnea and hemoptysis. Comparison of old and new CT scan showed increasing of cavity thickness. Lobectomy was performed and mucor was proved in histopathology.

**Conclusions:** We present two cases of pulmonary mucormycosis who referred with hemoptysis and other respiratory tract symptoms and lung cavitations. Surgical resection and amphotericin was very successful in their management. We recommend investigation of fungus in BAL fluid or tissue material of patients with cavitory lesion.

**Keywords:** Mucormycosis, Lung abscess, Lung cavitations

### Introduction

Zygomycosis is a relatively rare infection and classified into two types: Mucorales (Mucormycosis) and Entomophthorales. Both of these can infect humans. It is impossible to differentiate these two types

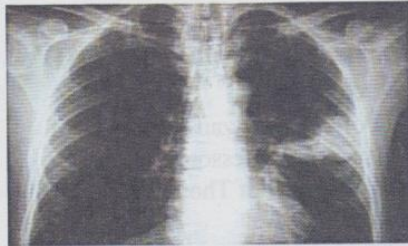by histopathological and epidemiological grounds and only culture is useful. In this article we present two cases with pulmonary mucormycosis.

### Report of cases

Case 1: A 58 year old diabetic man presented with cough and purulent sputum without odor. Three weeks later he developed hemoptysis.

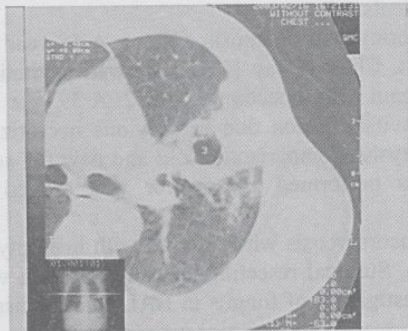Mirsadraee M. MD  
Address: No 80, 15<sup>th</sup> Kosar, Vakilabad BLV, Mashad  
E-mail: Majidmirsadraee@yahoo.com  
Acceptation date: 83/5/6 Confirmation date: 83/9/7

A chest X-ray (figure 1a) showed a round mass lesion in posterior segment of left upper lobe of approximately 7 cm in diameter. He then started to experience significant weight loss without any dyspnea or chest pain.



**Figure 1a:** Chest X-ray

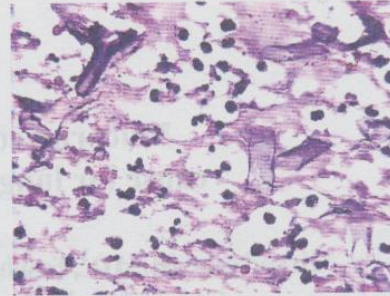
A chest CT scan showed a thick wall cavity in the left upper lobe (figure 1b).



**Figure 1b:** CT scan of patient with mucormycosis

Blood profile showed leukocytosis with neutrophilic predominance, anemia, and increased serum glucose. Bronchoscopy showed mild inflammation in the left upper lobe bronchus and biopsy showed thick wall cuboid broad non-septate hypha with right angle branching on the surface of the bronchus.

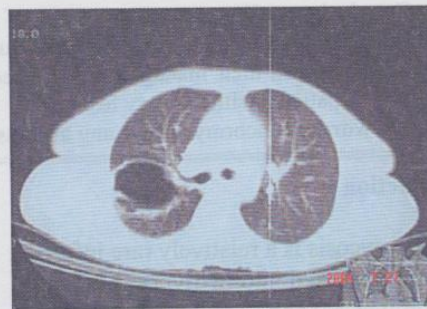
There was no response to antibiotic therapy. Surgery and lobectomy were performed, and neutrophilic reaction and mucor infiltration were confirmed figure 2.



**Figure 2:** Microscopic appearance of lung tissue with broad nonseptated hypha that had straight angulations representative of mucor and neutrophilic infiltrate.

Treatment was planned by control of diabetes and using Amphotericin. New chest X-ray showed complete resolution.

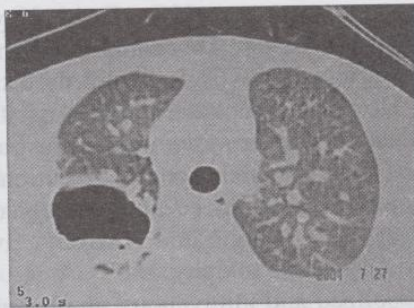
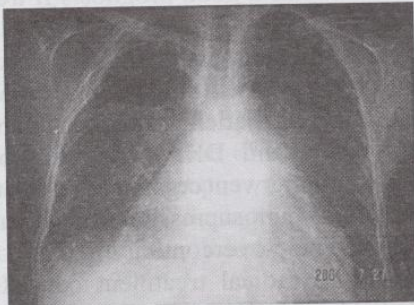**Case 2:** A 39 year old female with end stage renal disease due to glomerulonephritis, who underwent renal transplantation 5 year ago. One year after transplantation she experienced serious necrotizing gram negative pneumonia that led to permanent cavitory lesion in the right lung figure 3a.



**Figure 3a:** Uncomplicated cavitory lesion

With medical treatment she improved until 9 months ago when a transplanted kidney was rejected, and she was returned to chronic dialysis and immunosuppressive drugs were stopped. Two weeks before admission she experienced dyspnea and cough without hemoptysis.

New CT scan of the chest showed thickening of cavity with nodularity (figure 3b and 3c), finding compatible with mycetoma, and new pleural reaction. Surgery was performed and revealed green sludge material that proved to be mucor hypha in histopathology.



**Figure 3b-3c:** that was later infected with mucor fungi (CXR in figure 3b and CT scan in figure 3c)

### Discussion

Mucormycosis which is the most common type causing human infections, is specified by a rapid clinical course, significant tissue destruction, and invasion of blood vessels. This infection tends to grow on necrotic tissue, and it is most prevalent in immunocompromised hosts and diabetic patients. Humans may be exposed to Mucor through the inhalation of airborne fungal spores. However, normal macrophage and neutrophil function provides immune protection against the fungus.

Patients with neutrophil dysfunction, i.e. in diabetes, renal failure, or prolonged steroid therapy, are particularly vulnerable to the infection with Mucor. Additionally, neutropenic patients may also develop invasive mucormycosis. The first case of pulmonary mucormycosis reported in 1876 by Fur Bringer (3). Male to female ratio is 3 to 1, and mean age is 44 years (2-83).

These organisms have wide ecologic distribution, rapid growth and thermal tolerance that are particularly important for human pathogenesis. Most of the patients had underlying conditions like diabetes mellitus, hematological malignancies (4,5), chronic renal failure, organ transplantation and drug (Deferoxamin) and obstructive lung disease (7,9).

However, 13% of the cases had no underlying condition. Pulmonary mucormycosis in neutropenic and bone marrow transplant patients has been reported much more commonly than diabetes, renal transplantation or HIV disease. Onset of disease is acute (<30 days) in 78% and chronic (>30 days) in 22%. Most presenting symptoms are nonspecific, mainly with cough in 61% and fever in 63% of the patients (table 1) (1).

**Table 1:** Presenting symptoms and physical findings in patients with pulmonary Mucormycosis (1)

Presenting Symptoms	Patients		Physical Findings	Patients	
	No	%		No	%
Fever	55	54	Fever (Temp>38°C)	55	63
Cough	53	61	Tachypnea	20	23
Chest pain	32	37	Crackles	21	24
Dyspnea	25	29	Decreased breath sound	15	17
Hemoptysis	23	26	Wheezing	13	15

A classical presentation of a patient with mucormycosis could be fever, pulmonary infiltration or cavity formation that is refractory to antibiotic treatment.

All of our cases had hemoptysis as a major clinical finding. A wide variety of pulmonary manifestation exists (8), including solitary nodule, segmental or lobar consolidation, cavity and bronchopneumonic lesions (table 2)(1).

**Table 2:** Radiological manifestation of pulmonary mucormycosis (1)

Distribution	Patients		Pulmonary Findings	Patients	
	No	%		No	%
Upper part	39	45	Infiltrate	34	39
Middle part	3	3	Cavity	23	26
Lower part	18	21	Consolidation	18	21
Unilateral	5	6	Air crescent sign	7	8
multilobular			Pleural effusion	7	8
Bilateral	14	16	Fungus Ball	2	2
Hilar or mediastinal	3	3			

Most patients (43%) have involvement of the upper lungs as both of the cases presented here. However, 4% present with normal CXR because of tracheal or pulmonary artery involvement, or mucor related multiple pulmonary infarcts (9).

43% of patients with cavitory lesions have chest pain and hemoptysis. Pleural effusion is not a common feature (8%). Finding a fungus ball (like our second presented case) can be another radiological presentation(10). Zucormycosis tends to cause endobronchial lesions and 34 of 35 cases patients have positive bronchoscopy findings such as stenosis (24%), erythematous mucus (18%), obstruction and fungating or polypoid mass (12%). Bronchoalveolar lavage is a good way to confirm the diagnosis.

In a previous study, two of five patients were diagnosed by identifying the typical hypha of mucormycosis in the BAL fluid alone (11).

Untreated disease can invade compartments causing subsequent dissemination to both thoracic and distant extra pulmonary tissues (12,13). Our presented cases of mucormycosis

with nonspecific symptoms showed that high suspicion of physician and performing relevant investigations resulted in satisfactory treatment of the condition. This high level of suspicious is most important in diabetic patients in whom the disease has a rapid course which can simulate a bacterial infection and has a good prognosis if treated correctly (14,15).

Treatment is primary based on correction of underlying cause (highest resolution is seen in diabetic patient after treatment of hyperglycemia and DKA). In neutropenic patients who underwent organ transplantation, reducing immunosuppression and using GMCSF can help overcoming infection.

Otherwise radical treatment consists of resection of infected area such as lobectomy or pneumonectomy. Hyperbaric oxygen therapy and daily IV administration of Amphotericin B for 6 weeks are used there after. However, amphotericin B toxicity is well described after systemic administration and a local bronchoscopic injection of amphotericin B could be alternatively used to treat the lesion and thereby avoid potential systemic toxicity.

Aerosolized and intravenous amphotericin B preparations were also used successfully as adjunctive therapy in the treatment of this patient (16).

#### References

- 1- Lee F, Massad S, Adel K. Pulmonary Mucormycosis the last 30 years. Arch Intern Med 1999; 159:1301.
- 2- Baker RD. Mucormycosis. In: The pathologic anatomy of mycosis. Human infection with fungi actinomyces and algae New York: Springer Verlag NY inc; 1971.p. 832-918.
- 3- Furbringer P. Beobachtungen uber lungenmycose beim menschen. Arch Pathol Anat Physiol Klin Med 1876; 66: 330-365.
- 4- Nosari A, Oreste P, Montillo M, Carrafiello G, Draisci M et al. Mucormycosis in hematologic malignancies:

- an emerging fungal infection. *Hematologica* 2000; 85:1068-71.
- 5- Wohlrab JL, Anderson ED, Read CA. A patient with myelodysplastic syndrome, pulmonary nodules, and worsening infiltrates. *Chest*. 2001; 120 (3): 1014-7.
- 6- Spira A, Brecher S, Karlinsky J. Pulmonary mucormycosis in the setting of chronic obstructive pulmonary disease. A case report and review of the literature. *Respiration* 2002; 69 (6): 560-3.
- 7- Maniwa K, Tanaka E, Taguchi Y, Oida K, Inoue T et al. A case of abrupt pulmonary infection by *Rhizopus microsporus* var. *rhizopodiformis* during treatment for bronchial asthma. *Kansenshogaku Zasshi* 2002; 76 (5):396-9.
- 8- Chauhan BR, Gupta DK, Kaushal SS, Pal LS, Nada R. Pulmonary mucormycosis. *Journal of the Association of Physicians of India* 1998; 46 (4): 396-7.
- 9- Adams HP, Rosado M, Strollo DC, Patz EF. Pulmonary mucormycosis: radiologic findings in 32 cases. *American Journal of Roentgenology* 1997; 168 (6):1541-8.
- 10- Lahiri TK, Agarwal D, Reddy GE, Bajoria A. Pulmonary mucoraceous fungal ball. *Indian Journal of Chest Diseases and Allied Sciences* 2001; 43 (2):107-10.
- 11- Glazer M, Nusair S, Breuer R, Lafair J, Sherman Y et al. The role of BAL in the diagnosis of pulmonary mucormycosis. *Chest* 2000; 117(1):279-82.
- 12- Kitabayashi A, Hirokawa M, Yamaguchi A, Takatsu H, Miura AB. Invasive pulmonary mucormycosis with rupture of the thoracic aorta. *Am J Hematol* 1998; 58: 326-9.
- 13- Kim N, Barrie J, Raymond G. Pulmonary mucormycosis with angioinvasion of the left subclavian artery. *Canadian Association of Radiologists Journal* 2002; 53(5): 312-4.
- 14- Bhansali A, Suresh V, Chaudhry D, Vaiphei K, Dash RJ et al. Diabetes and rapidly advancing pneumonia. *Postgraduate Medical Journal* 2001; 77(913):734-5, 740-1.
- 15- Bhowmik D, Dinda AK, Khilnani GC, Mahajan S, Gupta S et al. Pulmonary mucormycosis in a diabetic renal transplant patient. *Indian Journal of Chest Diseases and Allied Sciences* 2002 ; 44 (4):275-7.
- 16- Zaizen Y, Ohtsu T. Successful treatment of pulmonary mucormycosis, a rare pulmonary fungal infection in a patient with diabetes mellitus. *Journal of Thoracic and Cardiovascular Surgery* 2002; 124(4):838-40.

\*\*\*\*\*

## خلاصه

## موکورمایکوزیس ریه، یک علت نادر برای کاویتاسیون ریه

## گزارش مورد

دکتر مجید میرصدرايي، دکتر محمد توحيدى، دکتر داوود عطاران، دکتر نوريه شريفى،

دکتر تقى عيائى مقدم، دکتر على صدرى زاده

**مقدمه:** ضایعات حفره ای ریه یکی از بیماریه های جدی ریه می باشد. از جمله موارد نادر بیماری های حفره ای ریه موکورمایکوزیس است که از جمله عفونت های قارچی ریه می باشد که اخیراً کمتر به آن توجه می شود و تشخیص به موقع و درمان آن به خصوص در دیابت و سرکوب ایمنی برای بیماران بسیار نمربخش می باشد.

**معرفی بیمار:** بیمار اول: آقای ۵۸ ساله که با سابقه دیابت به علت خلط خونی (هموپتیزیس) مورد بررسی رادیوگرافی ریه واقع شده و در آن حفره (کاویته) تشخیص داده شده و در برنکوسکپی هایفای موکورمایکوزیس مشخص شده و با لوبکتومی و درمان با آمفوتریسین کاملاً بهبود داشته اند. بیمار دوم: خانم ۳۹ ساله با سابقه نارسایی کلیه و حفره در ریه به علت پنومونی نکروزان قبلی دچار سرفه، تنگی نفس و خلط خونی می شود. در مقایسه دو CT scan قطر حفره زیاد شده که با لوبکتومی وجود موکور ثابت می شود.

**نتیجه گیری:** در این مطالعه ما، دو بیمار مبتلا به زیگومایکوزیس (موکورمایکوزیس) که به علت هموپتیزیس و ضایعات حفره ای ریه و سایر علائم ریوی دچار ناراحتی بوده اند معرفی شده اند. درمان این بیماران به وسیله ترکیب جراحی و آمفوتریسین موفقیت آمیز بوده است. توصیه ما بررسی قارچ در ترشحات شستشوی برنش بیماران مبتلا به ضایعات حفره ای ریه است.

**واژه های کلیدی:** زیگومایکوزیس، موکورمایکوزیس، آبسه ریه، کاویتاسیون ریه

43% of patients with pulmonary mycetozoa have positive findings. Pleural effusion is not a common feature (8%). Finding a fungus ball (like our second presented case) features disease (10). Zygomycosis tends to cause endobronchial lesions and 34 of 35 cases patients have positive bronchoscopy findings such as stenosis (26%), erythematous nodule (18%), obstruction and fungating or polypoid mass (12%). Bronchoalveolar lavage is a good way to confirm the diagnosis.

In a previous study, two of five patients were diagnosed by identifying the typical hypha of mucormycosis in the BAL fluid alone (11).

Untreated disease can invade compartments causing subsequent dissemination to both thoracic and distant extra pulmonary tissues (12,13). Our presented cases of mucormycosis

16).  
 16).  
 16).

## References

- 1- Lee E, Massel S, Adel K. Pulmonary mucormycosis: the last 30 years. Arch Intern Med 1999; 159:1301.
- 2- Parker RJ. Mucormycosis. In: The pathologic anatomy of mycosis. Human infection with fungi actinomyces and algae. New York, Springer Verlag NY inc, 1971; p. 832-918.
- 3- Furringer P. Beobachtungen ub. lungennmycose beim menschen. Arch Pathol Anat Physiol Klin Med 1876; 60: 130-165.
- 4- Nosari A, Cresti F, Mondillo M, Carralillo G, Drusci M et al. Mucormycosis in hematologic malignancies.